

MINERVA

STOMATOLOGICA

VOLUME 67 · SUPPL. I · No. 3 · JUNE 2018

**ONJ UPDATE 2018**  
**Osteonecrosi delle ossa mascellari (ONJ)**  
**da bifosfonati e altri farmaci:**  
**prevenzione, diagnosi, farmacovigilanza,**  
**trattamento**

Alessandria, 5 maggio 2018

Presidente: Dott. Vittorio Fusco



EDIZIONI · MINERVA · MEDICA

**ONJ UPDATE 2018**  
**Osteonecrosi delle ossa mascellari (ONJ)**  
**da bifosfonati e altri farmaci:**  
**prevenzione, diagnosi, farmacovigilanza,**  
**trattamento**

Alessandria, 5 maggio 2018

Presidente: Dott. Vittorio Fusco

---

# ABSTRACT

---

## CASE SERIES

### A01 - Relationship between periodontal disease and medical osteonecrosis of the jaw

M. Nisi, S. Mariotti, D. Bisordi\*, F. Graziani, M. Gabriele

*Department of Surgical, Medical and Molecular Pathology and Critical Care Medicine, University of Pisa, Pisa, Italy*

**BACKGROUND:** Medication-related osteonecrosis of the jaw (MRONJ) is a side effect of antiresorptive medications (IV and oral BPs, rank ligand inhibitor like denosumab) and (antiangiogenic medications). Patients may be considered to have MRONJ if all of the following characteristics are present: 1. Current or previous treatment with antiresorptive agents; 2. Exposed bone or bone that can be probed through an intraoral or extraoral fistula in the maxillofacial region 3. No history of radiation therapy to the jaws or obvious metastatic disease to the jaws. Several studies have focused on the risk factors for developing MRONJ. In the recent position paper of the American Association of Oral and Maxillofacial Surgeons (AAOMS), MRONJ risk factors are categorized as drug-related, local, demographic and systemic or genetic. The aim of the present study is to evaluate the prevalence and severity of periodontitis (P) in a cohort of patients affected by MRONJ. **METHODS:** The study included all consecutive subjects diagnosed with MRONJ in the Department of Dentistry and Oral Surgery of the University Hospital of Pisa from January 2004 to December 2017. MRONJ diagnosis was made according to the criteria proposed by the American Association of Oral and Maxillofacial Surgeons (AAOMS). Included subjects had a full-mouth periodontal examination on six sites per tooth involving all dentition. Clinical periodontal parameters were probing depth, gingival recession, plaque index and bleeding on probing.

**RESULTS:** Two hundred and twenty-four patients with MRONJ were included (162 females, mean age 68.9 years, SD 10,42 range 32-93). 162 patients (72,2%) received intravenous bisphosphonates (zoledronic acid 4mg IV) for the treatment of oncologic pathologies: metastatic breast cancer (65 patients, 29%), multiple myeloma (44 patients, 19,6%), metastatic prostate cancer (31 patients, 13,8%) and metastatic lung cancer (17 patients, 7,6%). Sixty patients were receiving oral BPs for the treatment of osteoporosis, while two patients (1%) received Denosumab for the treatment of metastatic breast cancer. 66% of the MRONJ lesions were located in the mandible; in 13 cases patients presented a lesion both in the maxilla and in the mandible. Fifty-eight patients did not show any periodontal involvements, 52 patients were edentulous whereas the remaining 114 had periodontal disease representing the 66% of the sample. Among the ones diagnosed by periodontitis the 3.5%, 5.6% and 90.9% were of mild, moderate and severe P, respectively.

**CONCLUSIONS:** The prevalence of P in patients affected by MRONJ is higher than literature data referring to MRONJ-free populations.

## REFERENCES:

- 1.. Diniz-Freitas M, Fernández-Feijoo J, Diz P, Pousa X, Limeres J. Denosumab-related osteonecrosis of the jaw following non-surgical periodontal therapy: A case report. *J Clin Periodontol.* 2018 Feb 26.
2. Ruggiero SL, Dodson TB, Fantasia J, Goodday R, Aghaloo T, Mehrotra B, O’Ryan F. American Association of Oral and Maxillofacial Surgeons position paper on medication-related osteonecrosis of the jaw--2014 update. *J Oral Maxillofac Surg.* 2014 Oct;72(10):1938-56.

### A02 - Ten years of clinical experience in medication-related osteonecrosis of the jaw

S. Franchi, E. Broccardo, M. Bonaso, A. Tavolaccini\*, A. Benecch

*Unit of Oral and Maxillofacial Surgery, Maggiore della Carità University Hospital, University of Eastern Piedmont Amedeo Avogadro, Novara, Italy*

**BACKGROUND:** Medication-related osteonecrosis of the jaw (MRONJ) represents the main side effect of Bisphosphonates (BP) and Denosumab. This work was made to report data and clinical experience of the Oral and Maxillofacial Surgery Unit of the Maggiore della Carità University Hospital of Novara in monitoring and treating MRONJ between January 2008 and December 2017.

**METHODS:** Patients with MRONJ admitted to the clinic received detailed investigation of their medical history and underwent a thorough clinical examination. According to the clinical evaluation, options for treatment included: 1) Non-surgical treatment with Chlorhexidine 0.20% mouth-wash rinses in combination with broad spectrum antibiotic therapy; 2) Non-aggressive surgical treatment: mucosal and bone debridement, removal of spontaneous bone sequestra; 3) Radical resection of necrotic bone. All patients were added to scheduled follow-up and clinical findings were registered in the medical record.

**RESULTS:** Patients presenting with MRONJ were 66; 55 patients (83,3%) had received a treatment with BP or Denosumab for oncologic or haematological disease (breast cancer: 19 cases, prostate cancer: 8 cases; multiple myeloma: 16 cases; lung cancer: 6 cases; kidney cancer: 1 case; non-Hodgkin Lymphoma: 3 case; colorectal cancer: 1 case; bladder cancer: 1 case), while 11 patients (16,7%) had been treated for osteoporosis. Most of oncologic or haematological patients (48 out on 55, 87,3%) had received intravenous administration of Zoledronate, while most of osteoporotic patients (9 out on 11, 81,8%) had received oral treatment with Alendronate. Only 2 patients had received treatment with Denosumab, but they also had been previously treated with BP. In addition to the treatment with BP or Denosumab, 20 patients (30,3%) had also received high dosage corticosteroids for at least 1 year. Out of the 66 patients, 15 (22,7%) had been visited by a Dentist or a maxillofacial surgeon before BP administra-

tion, and out of these, 7 (46,7%) had needed dentoalveolar surgery. 31 patients (47,0%) had undergone oral examination after having already received BP treatment, and 23 of them (74,2%) had needed dental extraction. Finally, 20 patients (30,3%) presented with MRONJ at the first evaluation and had a spontaneous onset. Stages of MRONJ at presentation were the following: Stage 1: 49 cases (74,2%); Stage 2: 14 cases (21,2%); Stage 3: 3 cases (4,6%). All patients presenting MRONJ received a prescription of Chlorhexidine 0,20% mouth rinses and antibiotic therapy; in 3 cases (4,6%) this non-surgical approach allowed complete healing. A surgical treatment was needed for other patients: 41 patients (62,1%) achieved complete healing with a less aggressive surgical treatment in the office; while for 22 (33,3%) office treatment was not sufficient, so they underwent radical surgery under general anesthesia. 8 of these 22 patients (36,4%) did not achieve complete healing despite the aggressive treatment; however, subsequent non-surgical treatment allowed healing of the recurrence in 3 cases (37,5%).

**CONCLUSIONS:** A less aggressive surgical approach seem to allow for healing in the majority of patients. While non-surgical treatment has a low success rate in healing the primary MRONJ, it appears to be of some effectiveness in treating relapses after radical surgery. Although surgical prophylaxis before BP or Denosumab administration helps in preventing onset of MRONJ, at the present, complete avoidance of this side effect does not appear possible. Further efforts should be prompted towards systematic preliminary evaluation and scheduled follow-up of the patients at risk of MRONJ.

**REFERENCES:**

1. Bedogni A, Campisi G, Agrillo A *et al.* Raccomandazioni clinico-terapeutiche sull'osteonecrosi delle ossa mascellari associata a bisfosfonati e sua prevenzione. Cleup. Padova, 2013.
2. Favia G, Tempesta A, Limongelli L *et al.* Medication-related osteonecrosis of the jaw: Surgical or non-surgical treatment? Oral Dis. 2018;24:238-42.
3. Khan AA, Morrison A, Hanley DA *et al.* Diagnosis and management of osteonecrosis of the jaw: a systematic review and international consensus. J Bone Miner Res. 2015;30:3-23.

**A03 - Medication-related osteonecrosis of jaw (MR-ONJ) in osteoporosis patients: recent experience data from Piedmont – Aosta Valley**

M. Cabras\*, A. Gambino, V. Fusco, O. Bertetto

*ONJ Study Group, Rete Oncologica di Piemonte e Valle d'Aosta, Torino (Italy) on behalf of Oral Medicine and Surgery Units : Torino (CIR Dental School, University of Turin; Dept Oncology, Oral Medicine and Oral Oncology, S.Luigi Gonzaga, University of Turin; Maxillofacial Surgery Unit, Città della Salute e della Scienza di Torino; Dentistry Section, Martini Hospital; Oral Care Unit, Mauriziano Hospital ; Maxillofacial Surgery Unit, S.G.Bosco Hospital ) and: Maxillofacial Surgery (Alessandria); Maxillofacial Surgery (Asti); Maxillofacial Surgery (Aosta); Dental Clinic, Department of Health Science, University of Eastern Piedmont (Novara); Maxillofacial Surgery (Novara) ; and other dental units and offices (Biella; Ciriè; Fossano; Verbania)*

**BACKGROUND:** Osteonecrosis of Jaws (ONJ) related to bisphosphonates (BP) or denosumab is a concern for osteoporosis and Rheumatoid Arthritis (RA) patients. Treatments

determining ONJ risk and proposed for prevention and/or treatment of osteoporosis include: oral alendronate (70 mg/week); oral risedronate (35 mg/week); iv ibandronate (3 mg q3months); oral ibandronate (150 mg monthly); yearly iv zoledronic acid (5 mg q12months); sc denosumab (60 mg q6months). All these agents showed possible induction of ONJ, described by some Authors as “rare” (1/1.000-1/10.000, according to WHO) or “very rare” (<1/10.000)(Adler *et al.*2016). Actually, evaluations about the individual ONJ risk are uncertain, due to bias in old trials (unknown ONJ; short-term follow-up; etc) and in recent trials (very restricted ONJ definition; limited observation time). Vice versa, real life ONJ cases after BPs and/or denosumab treatment in osteoporosis patients are not so rare (even if probably underdiagnosed), exceeding the ONJ cases in metastatic cancer patients in some countries (eg, Korea). As an almost unique experience, a multidisciplinary study group collected data of cases of ONJ in patients treated with BPs in oncology and hematology centers of a regional network (Piemonte–Valle d’Aosta), and among patients followed in the main dental care and maxillofacial surgery centers of the area. Between 2004 and December 2008, out of 241 total ONJ registered cases, 20 pts (8.3%) had ONJ diagnosis after BP therapy for bone disease different from bone metastases or myeloma (i.e., osteoporosis, osteopenia, RA, Paget’s disease, etc.) (Fusco *et al.* ISRN Oncology 2013).

**METHODS:** The survey was repeated, asking for ONJ cases observed between January 2009 and March 2017. We identified cases after cross-checking reports from medical oncology, hematology, and oral care centers to avoid double count and to integrate data. Results. We received sufficient data about 469 cases: 370 advanced cancer patients (78%) and 99 patients treated for other diseases (22%), but other osteoporosis cases lacked of some data. Characteristics of full data 99 osteoporosis cases have been analyzed. Sex: female/male 96%/4%. Disease: osteoporosis 85%, AR 10%, other 5%. Main administered drug : alendronate 64%, ibandronate 16%, risedronate 8%, zoledronate 6%, denosumab 3%. Number of cases per year: median 10 (range 7-16). Main site : mandible 70%, Maxilla 30%.

**CONCLUSIONS:** Preliminary data show increase of ONJ cases in patients receiving BPs or denosumab for osteoporosis and RA. The median number of cases per year in osteoporosis patients clearly increased in years 2009-2015, in comparison with years 2004-2008. Local visits to collect complete data of all cases (duration and doses of therapy; concomitant treatments and diseases; oral health risk factors) are ongoing, whenever possible. The collection of full clinical data is warranted to explore clinical figures and risk factors in this large osteoporosis patient population.

**REFERENCES:**

1. Adler RA *et al.* Managing osteoporosis in patients on long-term BP treatment: report of a Task Force of the ASBMR, JBMR 2016
2. Fusco *et al.* Decreasing Frequency of Osteonecrosis of the Jaw in Cancer and Myeloma Patients Treated with Bisphosphonates: The Experience of the Oncology Network of Piedmont and Aosta Valley (North-Western Italy) ISRN Oncology 2013
3. Campisi, L. Lo Russo, *et al.* BRONJ expert panel recommendation of the Italian Societies for Maxillofacial Surgery (SICMF) and Oral Pathology and Medicine (SIPMO) on Bisphosphonate-Related Osteonecrosis of the Jaws: risk assessment, preventive strategies and dental management. It J Maxillofac Surg 2011; 22:103-24

#### **A04 - Clinical course and therapeutic outcomes in medication-related osteonecrosis of the jaw. Our experience in the last two years**

M. Caka\*, M. Austa, P. Asperio, E. Margaglia, M. Daneo

*Unit of Oral and Maxillofacial Surgery, Cardinal Massaia Hospital, Asti, Italy*

**BACKGROUND:** Bone metastases develop in up to 75% of patients with advanced breast and prostate cancer, often leading to pathologic fractures and spinal cord compression requiring palliative radiation or orthopedic surgery. Common antiresorptive medications include bisphosphonates (BP) and the fully human monoclonal antibody denosumab. Both BP and denosumab have been implicated in medication related osteonecrosis of the jaw (MRONJ), as defined by the American Association of Oral and Maxillofacial Surgeons (AAOMS). The aim of this study was to analyze the clinical characteristics, disease course, examine operative and non operative therapeutic outcomes and to report the experience of Oral and Maxillofacial Surgery Unit of Cardinal Massaia Hospital, Asti in management of patients with MRONJ between January 2016 and December 2017.

**METHODS:** The study population was composed of 25 patients presenting for evaluation and management of MRONJ between January 2016 and December 2017. Most patients were female (22/25), with an average age of 72,9 ± 11,8 years (range: 47-87 years). Average follow up was 15,56 ± 8,86 months (range 3-26 months). Patients with follow up less than three months were excluded from analysis. A retrospective medical record was conducted and data were collected, including clinical findings, management, healing outcomes, and radiologic, histologic, and micro-computed tomography (CT) analyses.

**RESULTS:** 25 patients with explicit bisphosphonates (BP) and denosumab history presented MRONJ. Patients were treated for metastatic breast cancer (9/25), metastatic prostate cancer (3/25), lung cancer (1/25), multiple myeloma (1/25), primary osteoporosis (7/25), and other (4/25). 11/25 had received intravenous administration of Zoledronate, 7 had received oral treatment with Alendronate. 8 patients had received treatment with Denosumab (3/8 patients had also been previously treated with Bps). The lesions were found most often in the mandible 16 subjects (64%), in the maxilla 6 cases (24%) and both jaws 3 patients (12%). The majority of lesions were observed at sites of dental prostheses (43%), dental extractions (32%) and periodontitis (7%) or others (18%). 19/25 patients were managed operatively with either major (8/19) or minor surgery (11/6) and 6/25 patients were managed non-operatively. Major operative intervention demonstrated more complete healing (77%) compared to non-operative management of patients (23%) with MRONJ. Radiographic analysis revealed sequestrum and periosteal reaction, and Micro-CT demonstrated trabecular thickening. Most of Histologic patients analysis revealed disorganized bone structure with decreased number of osteocyte lacunae and mixed inflammatory infiltrate.

**CONCLUSIONS:** Major operative intervention demonstrated more complete healing than non-operative treatment of patients with MRONJ. However, in patients with early stage MRONJ, conservative therapy avoiding any aggressive surgery can still be the correct choice for treatment. Therefore a systematic preliminary accurate evaluation and scheduled follow up represents the best way to prevent MRONJ or at least to make early diagnosis. Our clinical finding may be

limited and influenced by a small sample size, therefore, more expanded studies may occur to clarify and confirm these preliminary our findings.

#### **REFERENCES:**

1. Favia G, Tempesta A, Limongelli L *et al.* Medication-related osteonecrosis of the jaw: Surgical or non-surgical treatment? *Oral Dis.* 2018;24:238-42.
2. Sebastian Hoefert, Anna Yuan At al. Clinical course and therapeutic outcomes of operatively and nonoperatively managed patients with denosumab-related osteonecrosis of the jaw (DRONJ). *Journal of Cranio-Maxillo-Facial Surgery* 45 (2017)570-578.
3. Franco-Pretto E, Pacheco M, Moreno A at al. Bisphosphonate-induced osteonecrosis of the jaws: clinical, imaging, and histopathology findings. *Oral Surg Oral Med Oral Pathol Oral Radiol* 118: 408-417, 2014.

#### **A05 - Medication-related osteonecrosis of the jaws (MRONJ) from 2004 to 2018: increase of non-bisphosphonate-related osteonecrosis**

M. Frontera\*, A. Pizzo, G. Ghidini, M. Meleti, P. Vescovi

*Oral Medicine and Oral Surgery Laser Unit, University Center of Dentistry, Department of Medicine and Surgery, University of Parma, EMDOLA (European Master Degree in Oral Laser Applications), Parma, Italy*

**BACKGROUND:** Medication-related osteonecrosis of the jaws (MRONJ) is a serious pharmacological complication of therapy with bisphosphonates and some monoclonal antibodies as well as biologic agents. The aim of this study is to report the change in the use of such drugs over the years, highlighting the increase in the administration of non-bisphosphonate drugs and its impact on the risk of development of MRONJ.

**METHODS:** Three hundred and twenty-four patients (93 males and 231 females) affected by MRONJ, were visited and variously managed between January 2004 and March 2018 at the Centre of Oral Medicine and Laser Surgery of the Academic Hospital of the University of Parma. Patients were classified into three groups: Group 1 (G1) from January 2004 to December 2009; group 2 (G2) from January 2010 to December 2014 and group 3 (G3) from January 2015 to March 2018. G1 consisted of 148 (45.7%) patients of which 124 were cancer patients and 24 non-cancer patients. One hundred and twenty (37%) patients were classified in G2; among these, 84 were cancer patients and 36 non-cancer patients. G3 included 56 (17.3%) patients; 37 were cancer patients and 19 non-cancer patients. According to the classification of the American Association of Oral and Maxillofacial Surgeons (AAOMS) - 2014 Update – patients in the present study could be classified as follows: 11 (3.3%) Stage 0, 123 (38%) Stage 1, 136 (42%) Stage 2 and 54 (16.7%) Stage 3.

**RESULTS:** In G1, 135 patients were treated with bisphosphonates 15.5% alendronate, 14.1% pamidronate, 66.7% zoledronate) and 13 were administered with non-bisphosphonate drugs in combination with bisphosphonates (84.6% in association with zoledronate and 15.4% in association with pamidronate). In G2, 106 patients received only bisphosphonates (22.6% alendronate, 3.8% pamidronate, 59.4% zoledronate) and 14 were treated with non-bisphosphonates (35.7% Denosumab). Of the last 14 patients, 85.7% were treated through a bisphosphonate-associated therapy and 14.3% were receiving only non-bisphosphonate drugs. In G3, 36 patients were treated with bisphosphonates (19.6% alendronate, 33.9%

zoledronate) and 20 were treated with other non-bisphosphonate drugs (60% Denosumab). Among these 65% were treated through a bisphosphonate-associated therapy and 35% were only on non-bisphosphonates.

**CONCLUSIONS:** Within the whole group of patients with MRONJ, there has been an increase in the number of patients treated with non-bisphosphonate drugs (G1 8.8%, G2 11.7%, G3 35.7%). It is also worthy to note that among all the non-bisphosphonate drugs, there is an increase of the treatments with denosumab (G1 0%, G2 35.7%, G3 60%). Over the years, there has been a shifting from a therapy exclusively based on the use of bisphosphonates to the association between bisphosphonate and non-bisphosphonate, up to treatments with only non-bisphosphonate drugs. Clinicians are facing the occurrence of “new” MRONJs associated to non-bisphosphonate drugs, with an earlier onset, less linked to surgical treatments, compared to the “classic” bisphosphonates forms. Further future studies are needed to clarify differences in prevalence and incidence of MRONJ in patients receiving only non-bisphosphonate medications.

**REFERENCES:**

1. Ruggiero Salvatore L. “American Association of Oral and Maxillofacial Surgeons position paper on medication-related osteonecrosis of the jaw--2014 update”. *J Oral Maxillofac Surg.* 2014 Oct;72(10):1938-56.

**A06 - Osteonecrosis of jaw (ONJ): recent experience data from the “rete oncologica Piemonte – Valle d’Aosta” cancer network**

A. Gambino\*, M. Cabras, V. Fusco, G. Numico, O. Bertetto  
*Supportive Care and ONJ Study Group, Rete Oncologica di Piemonte e Valle d’Aosta, Torino (Italy) on behalf of - Oncology and Hematology Units: Torino (hospitals: Città della Salute e della Scienza; Amedeo di Savoia, Gradenigo, Martini, Mauriziano, S.G.Bosco, San Luigi Gonzaga-Orbassano; IRCC Candiolo), and hospitals of Alessandria, Alba-Bra, Aosta, Asti, Biella, Borgomanero, Casale Monferrato, Chivasso, Ciriè, Cuneo, Ivrea, Novara, Novi Ligure, Ovada, Savigliano; Tortona, Vercelli; Oral Medicine and Surgery Units : Torino (CIR Dental School, University of Turin; Dept Oncology, Oral Medicine and Oral Oncology, S.Luigi Gonzaga, University of Turin; Maxillofacial Surgery Units, Città della Salute e della Scienza e S.G.. Bosco hospitals; Dentistry Section, Martini Hospital; Oral Care Unit, Mauriziano Hospital) and: Maxillofacial Surgery Hospital Units of Alessandria, Aosta, Asti, Cuneo, Novara; Dental Clinic, Department of Health Science, University of Eastern Piedmont (Novara); and other dental units and offices (Biella; Ciriè; Fossano; Verbania)*

**BACKGROUND:** Osteonecrosis of Jaws (ONJ) is a concern in cancer and myeloma patients receiving Bisphosphonates (BPs), and/or denosumab (another antiresorptive drug) for bone metastatic disease. Epidemiology data are not univocal. As an almost unique experience, since 2005 a multidisciplinary study group collected data of ONJ cases in patients receiving Bisphosphonates due to metastatic bone disease in oncology and hematology centers of a regional network, and followed in the main dental care and maxillofacial surgery centers of that regional area. By December 2008, 221 cases were registered; the number of new ONJ cases per year in cancer and myeloma patients increased since 2004 until 2006 and then reduced (till to 21 cases on 2008). Several possible reasons of this “up and down” trend (shift from pamidronate to zoledronic acid; increase of ONJ awareness; diffusion of preventive dental

measures; late modifications of BP prescriptions) were hypothesized. Aim. In recent years, literature data showed increasing numbers of ONJ cases after denosumab or after other drugs (bevacizumab, sunitinib, etc), so that the new term Medication Related – ONJ (MRONJ) was introduced. Consequently, we decided to repeat the previous survey to verify the time trend in advanced cancer and myeloma patients.

**METHODS:** We asked for new ONJ cases observed between January 2009 and March 2016. We identified cases after cross-checking reports from medical oncology, hematology, and main oral care centers to avoid double count.

**RESULTS:** We received partial data about 370 cancer and myeloma patients. Sex: 65% female, 35% male. Primary disease: breast cancer 46%, myeloma 20%, prostate cancer 20%, other (lung, renal cell and other types of cancer or not specified) 13%. The median number of new cases per year was 46 (range 28-54) in years 2009-2016. Main administered drug : zoledronic acid 73%, denosumab 7%, pamidronate 4%, other BPs or antiangiogenic drugs alone 1%. Main site : mandible 67%, maxilla 33%. Local visits to collect complete data of all cases (duration and doses of therapy; concomitant treatments and diseases; oral health risk factors) are ongoing.

**CONCLUSIONS:** Preliminary data show an unexpected increase of new ONJ cases per year, in spite of measures prescribed to reduce the ONJ risk (recommended dental visit and oral care before antiresorptive treatment; careful evaluation of the case, if a tooth or root extraction is indicated during treatment). Possible reasons include: insufficient adoption of “preventative” measures; introduction of denosumab treatment in bone metastatic patients; larger use of biological agents potentially inducing ONJ; longer survival of some subsets of cancer patients (eg, lung and renal cell cancer, etc); in recent years; higher risk from antiresorptive plus antiangiogenic drugs. The collection of full clinical data is warranted to explore these suggestions.

**REFERENCES**

1. Fusco V *et al.* Decreasing Frequency of Osteonecrosis of the Jaw in Cancer and Myeloma Patients Treated with Bisphosphonates: The Experience of the Oncology Network of Piedmont and Aosta Valley (North-Western Italy) *ISRN Oncology* 2013
2. Campisi G., Lo Russo L, *et al.* BRONJ expert panel recommendation of the Italian Societies for Maxillofacial Surgery (SICMF) and Oral Pathology and Medicine (SIPMO) on Bisphosphonate-Related Osteonecrosis of the Jaws: risk assessment, preventive strategies and dental management. *It J Maxillofac Surg* 2011; 22:103-24.
3. Loyson T, Van Cann T, *et al.* Incidence of osteonecrosis of the jaw in patients with bone metastases treated sequentially with bisphosphonates and denosumab. *Acta Clin Belg.* 2017

**A07 - MRONJ in patients treated with antiresorptive or antiangiogenic agents: a two-year case series follow-up**

V. Zavaglia<sup>1</sup>, A. Nori<sup>1</sup>, M. Mascitti<sup>2\*</sup>, A. Tesi<sup>1</sup>, A. Santarelli<sup>2</sup>  
<sup>1</sup>Special and Surgical Stomatology Department, “Ospedali Riuniti” Hospital of Ancona, Ancona, Italy; <sup>2</sup>Department of Clinical Specialistic and Dental Sciences, Marche Polytechnic University, Ancona, Italy

**BACKGROUND:** Medication related osteonecrosis of the jaw (MRONJ) is a potential adverse effect related to the use

of several drugs, including antiresorptive and antiangiogenic drugs. This pathology is triggered by a continuity solution of the mucosa, such as dental extractions, and is characterized by the progressive bone destruction in the maxillofacial region. The presence of all the following characteristics may indicate that the patient is affected by MRONJ: current or previous treatment with antiresorptive or antiangiogenic agents; exposed bone or bone that can be probed through a fistula in the maxillofacial region that persists for more than 8 weeks; no history of head and neck radiotherapy or metastatic disease to the jaws. Regarding the pathogenesis, there are several hypotheses that could explain its unique localization to the jaws, involving inflammation and infection, bone remodeling suppression, and compromised angiogenesis. The aim of this retrospective study is to present a 2-year case series follow-up in a group of patients in treatment with antiresorptive (bisphosphonates, denosumab) or antiangiogenic agents for postmenopausal osteoporosis or bone metastases.

**METHODS:** 36 consecutive patients affected by MRONJ were divided in two groups on the basis of the pathology for which the drug was originally prescribed: group 1 (postmenopausal osteoporosis) and group 2 (oncologic patients). The patients were furthermore divided in 3 groups on the basis of previous/current administered therapy: group A (only bisphosphonate), group B (only denosumab), and group C (bisphosphonate + denosumab). All patients were treated against osteoclast-mediated bone loss due to bone metastases. Age, sex, type of therapy, systemic and local risk factors were recorded. Treatment depended on the stage of MRONJ, consisting in medical and minimally-invasive surgical procedures. Follow-up consists in regular clinical and radiological evaluation at days 10, 30, months 2, 4, 6, 8, 10, and 12, to ascertain the absence of recurrences.

**RESULTS:** 36 patients with MRONJ were selected (15 patients in group 1 and 21 in group 2). Our results showed a mean patient age of 68.2 years. According to MRONJ staging, 19 cases were Stage 1, 11 cases in Stage 2, and 6 in Stage 3. The lesions were predominantly located in the mandible ( $n = 27$ ). The most common predisposing factor was the presence of residual roots, while regarding systemic risk factors was long-term use of systemic corticosteroids. Seven cases of recurrent MRONJ were observed: 4 cases of Stage 2 MRONJ in group 1 and 3 cases of Stage 1 MRONJ in group 2. Regarding recurrence risk, no statistical differences were observed in the studied groups.

**CONCLUSIONS:** For prevention of MRONJ recurrences, periodical dental examinations are recommended.

#### REFERENCES:

1. Villa A, *et al.* Osteoporosis and bisphosphonate-related osteonecrosis of the jaw bone. *ISRN Rheumatol*, 2011.
2. Coropciuc RG, *et al.* Medication-related osteonecrosis of the jaw in oncological patients with skeletal metastases: conservative treatment is effective up to stage 2. *Br J Oral Maxillofac Surg*, 2017.

### **A08 - Lethal and life-threatening cases of osteonecrosis of jaw (ONJ) in cancer and osteoporosis patients: review of 14 literature cases**

A. Melito\*, M. Alessio, I. De Martino, A. Fasciolo, V. Fusco  
 "Centro Documentazione Osteonecrosi", *Oncology Unit, Maxillofacial Surgery Unit, Azienda Ospedaliera "SS. Antonio e Biagio e C. Arrigo", Alessandria, Italy*

**BACKGROUND:** Osteonecrosis of Jaw (ONJ), observed after Bisphosphonates (BPs), denosumab and other drugs,

is usually described as an event with mild or moderate severity, even if a negative impact on Quality of Life has been described and demonstrated. However, as a form of osteomyelitis with potential severe infective complications (necrotizing fasciitis, Ludwig's angina, sepsis, etc), ONJ can rarely be lethal or life-threatening (inducing intensive care in inpatient departments or emergency units).

**METHODS:** We reviewed the ONJ literature (Pub Med and other sources) looking for a large sums of keywords and MESH terms, including "osteonecrosis", "jaw", "lethal", "life-threatening", "Ludwig's angina", "necrotizing fasciitis", "sepsis", "death", etc.

**RESULTS:** We collected 80 papers and/or conference abstracts potentially referring to severe cases of ONJ history. After exclusions of those related to surgery complications or not related to the issue, 38 abstracts and papers were examined independently by two Authors. Finally we definitively analysed 14 cases reported in 13 papers or conference abstracts (including two cases observed at our hospital). Median age of cases was 65 years (range 55-83). Sex: 11 Females (F) and 3 Males (M). Seven cases were cancer patients (3 breast, 2 myeloma, 1 prostate, 1 renal disease; 5 F / 2 M) receiving intravenous BPs (5 zoledronic acid, 1 pamidronate, 1 ibandronate), with associated antiangiogenic drugs in 3: the 7 cases showed 6 lethal and 6 life threatening disease. Seven cases were patients with osteoporosis and non-malignant diseases receiving oral BPs (alendronate, risedronate, ibandronate) or iv BPs (zoledronic acid, pamidronate) or subcutaneous denosumab, or various drugs in different times; they were 6 F and 1 M; 3 out of 7 cases had a RA (Rheumatoid Arthritis) diagnosis; they were 3 lethal and 4 life-threatening cases.

**CONCLUSIONS:** Some ONJ patients can be at risk of life-threatening events or death correlated to ONJ complications. Female patients are apparently at higher risk. Osteoporosis patients (namely with a much lower incidence of ONJ in comparison with cancer patients) seem to demonstrate at least no lower risk of severe complications. RA patients must be particularly followed. Further pharmacovigilance and literature data are needed to study subset populations of ONJ cases with special aspects in clinical and drug history (ie, immunocompromised; treated with antiangiogenic and other special or new agents; with comorbidities; transplanted patients), in order to early recognize ONJ cases at higher risk of life-threatening or lethal complications.

#### REFERENCES:

1. L. Randi, I. De Martino, A. Fasciolo, A. Gambino, V. Fusco. Osteonecrosis of jaw (ONJ): sometimes a life-threatening event. Literature review and two case. *Ann Stomatol (Roma)* 2014 Apr-Jun; 5(2 Suppl): 33-34. Published online 2014 May 9. PMID: PMC4377653
2. Qaisi M, Hargett J, Loeb M, Brown J, Caloss R. Denosumab Related Osteonecrosis of the Jaw with Spontaneous Necrosis of Soft Palate: Report of a Life Threatening Case. *Case Rep Dent*. 2016;2016:5070187. doi: 10.1155/2016/5070187. Epub 2016 Aug 28
3. Viviano M, Addamo A, Cocca S. A case of bisphosphonate-related osteonecrosis of the jaw with a particularly unfavourable course: a case report. *J Korean Assoc Oral Maxillofac Surg*. 2017 Aug;43(4):272-275. doi: 10.5125/jkaoms.2017.43.4.272. Epub 2017 Aug 24

## A09 - Retrospective analysis of BP therapy in 1663 oncological and hematological patients between 2007 and 2016. Effect of dental prevention on ONJ incidence

M. Badea, G. Setti, L. Panari\*, U. Consolo, P. Bellini

*Unit of Dentistry and Oral-Maxillofacial Surgery, Surgical, Medical and Dental Department of Morphological Sciences related to Transplant, Oncology and Regenerative Medicine, University of Modena and Reggio Emilia, Modena and Reggio Emilia, Italy*

Real incidence of ONJ in oncological patients is still not completely defined due to limitations related to data collection and diagnostic classification. Aim of this study was to retrospectively measure incidence rate in a cohort of oncological and hematological patients, assisted by Oncological Centre of Modena (COM). A keyword research in the clinical report database was performed. The query was set for chemotherapy side effects; "osteonecrosis" keyword was researched through the recorded data. Investigation period was between January 1st 2007 and August 31st 2016. Moreover, data analysis included age and patient sex, histological tumor classification, time of first pathological diagnosis, results of dental examination prior therapy beginning, type of anti-resorptive drug, therapy type and duration, concomitant D vitamin administration. Reported ONJ cases were summarized and sorted by time of ONJ onset, stage, localization, number of drug administrations, ONJ treatment and outcome. Furthermore, lesions were classified as spontaneous or consequent to dental-alveolar surgery. Dental evaluation and support therapy for oncological patients (CLID Project) was activated by Oncological Center and Unit of Dentistry and Oral-Maxillofacial Surgery in 2010. Since the start, dentist, oral surgeon and dental hygienist cooperate for diagnosis, support and treatment of oncological patient in anti-resorptive therapy. Evaluation appointment, recall and therapy delivery are scheduled in accordance between dental and oncology specialist. To measure incidence, patient data from 2007 to 2016 were selected. Between this period, 1663 patient were assisted by COM and received bisphosphonate drug. 47 ONJ cases were reported, with a raw incidence of 2.8%. Disease affected 44 females and 19 males with mean age 69 y.o., at diagnosis (range 47-90) when age at oncological diagnosis was 63 y.o. (range 40-86). Higher ONJ incidence was in breast cancer patients (54%), followed by myeloma and hematological neoplasms (21%), prostate cancer (13%), kidney cancer (5%), lung cancer (5%) and other solid neoplasm (5%). To measure incidence 47 cases were split in two groups: treated between 2007-2010 (29) (no dental evaluation) and between 2010-2016 (18) (dental evaluation). Equally, 1663 BF patients were split between time periods; 711 (2007-2010) and 952 (2010-2016). Of 711 patients who received BF before 2010, 29 has developed ONJ (4,1%). On the other hand, of 952 BF patients only 18 ONJ occurred (1,9%). Within the limits of this study such as retrospective nature, heterogeneity, different drugs and schedules, concomitant oncological therapy and type of disease, we highlight the impact of dental prevention on incidence of ONJ.

### REFERENCES:

1. Migliorati CA, Epstein JB, Abt E, Berenson JR. Osteonecrosis of the jaw and bisphosphonates in cancer: a narrative review. *Nat Rev Endocrinol.* 2011;7(1):34-42. doi:10.1038/nrendo.2010.195.
2. Mozzati M, Arata V, Gallesio G. Tooth extraction in patients

on zoledronic acid therapy. *Oral Oncol.* 2012;48(9):817-821. doi:10.1016/j.oraloncology.2012.03.009.

3. Bamias A, Kastritis E, Bamia C, *et al.* Osteonecrosis of the jaw in cancer after treatment with bisphosphonates: Incidence and risk factors. *J Clin Oncol.* 2005;23(34):8580-8587. doi:10.1200/JCO.2005.02.8670.
4. *Oral Oncol.* 2012;48(9):817-821. doi:10.1016/j.oraloncology.2012.03.009.

## A10 - MRONJ: a case series of 20 patients visited at Sant'Orsola-Malpighi Hospital and Dental Clinic, University of Bologna

F. Pavanelli<sup>1</sup>\*, R. Parrulli<sup>1</sup>, A. Gabusi<sup>2</sup>, L. Montebugnoli<sup>2</sup>, C. Marchetti<sup>1</sup>

*<sup>1</sup>Unit of Oral and Maxillofacial Surgery, Department of Biomedical and Neuromotor Science (DIBINEM), University of Bologna, Bologna, Italy; <sup>2</sup>Section of Oral Science, Department of Biomedical and Neuromotor Science (DIBINEM), University of Bologna, Bologna, Italy*

**BACKGROUND:** The objective of this report is to show the clinical features of a series of patients affected by MRONJ and discuss the implications of these on the MRONJ appearance. **METHODS:** Patients about to start or already on therapy with Bisphosphonates (BPs) are sent by their treating physicians to the counseling clinics (Unit of Oral and Maxillofacial Surgery) to start a path of prevention or diagnosis and therapy of the MRONJ; during these visits all the data related to the patient medical and dental history are collected with particular attention to the MRONJ risk factors that are reported in the literature.

**RESULTS:** From January 2017 to December 2017 we have seen 78 patients treated with bisphosphonate drugs; among these patients 16 showed MRONJ at the first examination, 3 showed it during follow-up and 1 showed two distinct cases of MRONJ, one on first visit and the other during follow-up; 65% of the involved patients were women whereas 35% were men and the main age was 73 (range 56-88). On medical history, most of these patients (75%) presented metastatic carcinomas whereas 5% presented multiple myeloma and 20% osteoporosis. Drug: 80% of the patients had been on zoledronate therapy (1 patient of these received also denosumab) while 20% with alendronate; all the patients had already stopped the therapy at the time of the first visit. Based on the diagnosis, 79% of the MRONJ belonged to the stage 2 (2 patients of these showed 2 different MRONJ e another one 3 different MRONJ foci) and 21% to the stage 3; no stage 1 was detected. The main MRONJ location was the mandible (60%) followed by the maxilla (25%) and in the remaining cases (15%) there was an involvement of both the upper jaw and the maxilla. In 12 patients MRONJ appeared on a site of previous dental extraction (1 certainly under antibiotic prophylaxis, 2 with also severe periodontitis, 1 with also perimplantitis and 1 on therapy with corticosteroids); all patients received surgical procedures with prior BP drug holiday. Five patients had as local risk factor only severe periodontal disease, and other 2 only therapy with corticosteroids, while in the remaining patient no risk factors were detected.

**CONCLUSIONS:** From this small sample of patients it emerges the heterogeneity of the MRONJ, especially with regard to the duration of therapy with BPs. As for local risk factors, dental extractions with or not antibiotics prophylaxis seem to be the most important events, however the reason why this condition is not responsible for MRONJ in all patients



with apparently similar clinical history is not yet clear. Maybe an answer to this question can be found in the evaluation of a larger case series by placing more and more attention to the clinical conditions of the patients concerned.

#### REFERENCES:

1. Ruggiero SL, Dodson TB, Fantasia J *et al.* (2014) American association of oral and maxillofacial surgeons position paper on medication-related osteonecrosis of the jaw-2014 update. *J Oral Maxillofac Surg* 72(10):1938–1956
2. Dodson T.B: The Frequency of Medication-related Osteonecrosis of the Jaw and its Associated Risk Factors. *Oral Maxillofac Surg Clin North Am.* 2015 Nov;27(4):509-16.

### A11 - Prevalence of mandibular fracture among 328 patients with medication-related osteonecrosis of jaws (MRONJ)

A. Pizzo\*, M. Frontera, G. Ghidini, M. Manfredi, P. Vescovi  
*Oral Medicine and Oral Surgery Laser Unit, University Center of Dentistry, Department of Medicine and Surgery, University of Parma, Parma, Italy*

**BACKGROUND:** Definition of medication-related osteonecrosis of the jaws (MRONJ) include all of the following features:

- 1) Current or previous treatment with antiresorptive or antiangiogenic agents;
- 2) exposed bone or bone that can be probed through an intraoral or extraoral fistula in the maxillofacial region that has persisted for more than eight weeks and
- 3) no history of radiation therapy or obvious metastatic disease to the jaws.[1]

In advanced stages, pathologic mandibular fracture is a possible serious complication radically worsening patients quality of life. The purpose of the present retrospective study is to report the prevalence of mandibular fractures in a cohort of patients with MRONJ followed at the Center of Oral Medicine and Laser Surgery of the Academic Hospital of the University of Parma.

**METHODS:** Three hundred and twenty eight patients affected by MRONJ were visited and variously managed between January 2004 and March 2018 at the Center of Oral Medicine and Laser Surgery of the Academic Hospital of the University of Parma. There were 233 females (71%) and 95 males (29%). Among these, 247 were treated for an underlying oncological problem (75%) and 81 for non-oncological disease (25%). According to the staging system proposed by Ruggiero *et al.*[1], patients were classified as follows: 11 patients with Stage 0 (3%), 124 with Stage I (38%), 137 with Stage II (42%) and 55 with Stage III (17%).

**RESULTS:** Seven (12,7%) mandibular fractures occurred within the Stage III groups (5 females (71,4%) and 2 male (28,6%)). Two patients of such a group were treated for oncological reason and 5 for non-oncological. Four patients underwent dental extractions before developing MRONJ, 2 were classified as having “spontaneous” MRONJ and one patient developed the disease after placement of a dental implant. Only 2 of these smoked. Two patients were administered with zoledronic acid, two with alendronic acid, two with pamidronidic acid and only one took denosumab.

**CONCLUSIONS:** Pathologic mandibular fracture can occur both in cancer and non-cancer patients. It is usually a difficult event to manage because of the non-conservative treatment

required and the frequent very poor conditions of patients with Stage III MRONJ. In late years, prevention has led to a substantial reduction of the prevalence of MRONJ. The main target of management should be the prevention and early diagnosis of MRONJ in order to allow a conservative approach. On the basis of the current knowledge, evolution of ONJ is not predictable. Therefore, prevention of fractures can benefit from early treatment (possibly surgical) of MRONJ also at initial stages (stage I) in order to stabilize the disease and limit its evolution.

#### REFERENCES:

1. American Association of Oral and Maxillofacial Surgeons Position Paper on Medication-Related Osteonecrosis of the Jaw—2014 Update Ruggiero, Salvatore L. *et al.* *Journal of Oral and Maxillofacial Surgery*, Volume 72, Issue 10, 1938 - 1956

### A12 - Denosumab related osteonecrosis of jaw: a single center five-year experience

F. Testore\*<sup>1</sup>, M. Canicatti<sup>1</sup>, M. Daneo<sup>2</sup>, M. Austa<sup>2</sup>, V. Fusco<sup>3</sup>  
<sup>1</sup>*Oncology Unit, Ospedale di Asti, Asti, Italy;* <sup>2</sup>*Maxillofacial Surgery Unit, Ospedale di Asti, Asti, Italy;* <sup>3</sup>*Centro Documentazione Osteonecrosi, Alessandria, Italy*

**BACKGROUND:** Osteonecrosis of the jaw (ONJ) is observed after antiresorptive treatment of bone metastases in cancer patients, both after bisphosphonates and denosumab. Denosumab is a RANK-L inhibitor that showed to be at least as efficacious as zoledronic acid, with some advantages (subcutaneous injection instead of intravenous infusion; less nephrotoxicity) and disadvantages (cost).

**AIM:** In our Oncology Unit we replaced zoledronic acid with denosumab since 2013. We reviewed the frequency of ONJ in our patients receiving denosumab in latest 5 years

**METHODS:** We retrospectively reviewed records of patients with solid tumors and bone metastases treated with denosumab (as first treatment or after prior bisphosphonates) at our Oncology Unit, after previous dental visit at Maxillofacial Surgery Unit. In case of needed extractions of teeth or roots, the treatment was delayed till to healing of sockets.

**RESULTS:** We identified 211 patients receiving denosumab (120 mg every 28 days). The number of administered courses ranged between 1 and 58. Median number of months of treatment was 11 (range 1-55). Most of patients suffered for breast and prostate tumours; less frequent: melanoma; lung cancer; pancreas and biliary tract cancer; gynecological and urological cancers. At this moment, ONJ has been identified in 22 patients (17 treated with denosumab alone and 5 previously receiving zoledronic acid). Characteristics of 22 ONJ cases were analyzed. Sex: 14 female and 8 male. Year of start of denosumab treatment: 2013 in 8, 2014 in 7, 2015 in 4, 2016 in 3 cases. Year of ONJ diagnosis: 2014 in 3, 2015 in 6, 2016 in 8, 2017 in 5. Number of denosumab courses at the ONJ onset time: median 16 (range 3-45); 1-6 in 3 cases; 7-12 in 6 cases; 13-24 in 6 cases; 25-36 in 3 cases; more than 36 in 4 cases. Cancer type was breast in 12, prostate in 6, lung in 3, biliary tract in 1. Other drugs possibly inducing ONJ administered together with denosumab: bevacizumab in 2, everolimus in 2 patients.

**CONCLUSIONS:** Preliminary results of our centre analysis do not confirm the rate of 1% - 2% of “adjudicated” ONJ, according to AAOMS (American Association Oral Maxillofacial Surgeons) definition, in the three denosumab pivotal trials. Our results are more similar to those of a recent

Belgian center analysis (in which, however, no systematic dental evaluation was conducted before denosumab treatment), that showed ONJ rates of 10 % and 15.5 % after denosumab and zoledronic acid/denosumab respectively. We have planned actuarial analyses (Kaplan Meier) on the full population to evaluate ONJ risk on time.

REFERENCES:

1. Saad F, Brown JE, Van Poznacck *et al.* Incidence, risk factors, and outcome of osteonecrosis of the jaw: integrated analysis from three blinded active-controlled phase III trials in cancer patients with bone metastases. *Annals of Oncology* 2012; 23:1341-7
2. Loyson T, Van Cann T, Schöffski P, *et al.* Incidence of osteonecrosis of the jaw in patients with bone metastases treated sequentially with bisphosphonates and denosumab. *Acta Clin Belg.* 2017 Jul 10:1-10

**A13 - On-off, a new tool in collecting osteonecrosis of jaw (ONJ) clinical data. A single center preliminary experience**

M. Settineri\*, A. Fasciolo, I. De Martino, M. Alessio, V. Fusco "Centro Documentazione Osteonecrosi", Maxillofacial Surgery Unit, Oncology Unit, Azienda Ospedaliera "SS. Antonio e Biagio e C. Arrigo", Alessandria, Italy

**BACKGROUND:** Screening, diagnosis, primary and secondary prevention (risk reduction) of Osteonecrosis of Jaw (ONJ) after Bisphosphonates (BPs), denosumab, and other drugs are very complex. Large amounts of clinical and history data are to be collected, preserved and elaborated to study this relatively young disease. ON-OFF (OsteoNecrosis Oral findings & Future) is a new online web platform created to let doctors, dentists, scholars to insert data of the observed cases of ONJ and share data for clinical and scientific purposes. ON-OFF was launched after collaboration of University of Palermo and SIPMO (Società Italiana di Patologia e Medicina Orale), thanks to Olga Di Fede, Giuseppina Campisi and other specialists. The Alessandria Hospital ONJ Multidisciplinary Team was established on autumn 2005, after first ONJ cases (breast and prostate cancer and myeloma patients) were observed in our Hospital. The ONJ Multidisciplinary Team include maxillofacial surgeons / dentists, oncologists, hematologists, nurses, radiologists, nuclear medicine and infective disease specialists, data managers. At February 2018, we followed more than 700 patients : most of patients of Oncology and Hematology units candidate to receive BPs or denosumab, and about 50 patients cancer or osteoporosis referred by other hospitals (for consultation or second-opinion about ONJ or ONJ risk).

**AIM:** To insert data of previous and current ONJ cases observed by the Alessandria Hospital ONJ Multidisciplinary Team on the web ON-OFF system and to analyze the data; to evaluate availability and efficacy of the ON-OFF platform.

**METHODS:** We reviewed patients observed by our multidisciplinary team on years 2005-2017. We selected charts of all patients with ascertained or suspected diagnosis of ONJ to eventually charge their data on ON-OFF platform. We exploited all the masks of the platform: clinical history; drug history; visits; treatments, and we utilized the system of loading pictures (photos; Rx images; CT scans).

**RESULTS:** We reviewed charts of 100 patients classified as follows : 81 with ascertained diagnosis of ONJ according to the SIPMO-SICMF definition; 19 cases with suspected ONJ (not diriment imaging; under examination; suspected symptoms in

high-risk patients). Sex : F/M 59/41%. Drugs : 91% antiresorptive agents (BPs, denosumab), 9% others (antiangiogenic, ecc); zoledronic acid 61%, alendronate 11%, pamidronate 9%, denosumab 5%, ibandronate 6%, sunitinib 5%, bevacizumab 3%. Cancer disease 83% (breast 36%, prostate 20%, myeloma 8%, renal cell 8%, lung cancer 5%, etc) *versus* osteoporosis and non-malignant disease 17% (mostly osteoporosis and Rheumatoid Arthritis). First 40 charts (out of 81 cases) have been charged on the ON-OFF platform and the work is ongoing.

**CONCLUSIONS:** Even if with some amendable and improvable aspect, in our preliminary experience the ON-OFF platform was a very useful tool to register data of ONJ cases observed in our centre; the work will be completed. We hope that the ON-OFF system might be adopted by most of Italian centres and groups involved in the ONJ care and research, and that national studies might be performed on the several controversial aspects of the disease.

REFERENCES:

1. Bedogni A, Fusco V, Agrillo A, Campisi G. . Learning from experience. Proposal of a refined definition and staging system for bisphosphonate-related osteonecrosis of the jaw (BRONJ). *Oral Dis.* 2012;18(6):621-3.
2. A. Bedogni, G. Campisi, A. Agrillo, V. Fusco. Raccomandazioni clinico-terapeutiche sull'osteonecrosi delle ossa mascellari associata a bisfosfonati e sua prevenzione. Cleup Editore, Padova (2013). Available at www.sipmo.it
3. <http://www.sipmo.it/nuova-piattaforma-clinico-epidemiologica-per-osteonecrosi-delle-ossa-mascellari-da-farmaci/>

**CASE REPORT**

**B01 - Use of autologous platelet-rich fibrin (A-PRF and i-PRF) in the treatment of a massive medication-related osteonecrosis of the jaw (MRONJ)**

A. Antonelli, C. Buffone, F. Bennardo, Y. Brancaccio, A. Giudice

School of Dental Medicine, Department of Health Sciences, University "Magna Graecia" of Catanzaro, Catanzaro, Italy

Medication-related osteonecrosis of the jaw (MRONJ) is a recurring complication resulting from the long-term therapy with bisphosphonates or antiresorptive drugs. A 69-year-old male patient presented to our attention in October 2015 with pain and swelling mandible. Teeth 44 and 46 was extracted four months previously by a general dentist and the patient was referred to our department due the lack of extraction socket healing. Extraoral examination showed leakage of exudate with multiple fistulas in the symphysis area. The intraoral evaluation showed halitosis presence, widespread periodontal disease and the presence of exposed necrotic bone in the right mandibular region. The patient received Alendronate per os (70 mg/week) for ten years for the management of the severe osteoporosis. The radiographic findings (CT and OPT) evidenced changes to trabecular pattern dense woven bone and persistence of unre modeled bone in the right posterior mandible area. Clinical and radiological findings suggested the diagnosis of Stage 3 MRONJ according to SIPMO classification. The patient was initially treated conservatively with antibiotic, professional dental hygiene and mouth rinse with nystatin and chlorhexidine 0.2 %. Surgery was performed under local anesthesia and the protocol included the resection of all necrotic bone with piezoelectric surgery. Resection bone margins

were determined by the clinical appearance of bleeding bone. After bone resection the surgical site was filled with autologous platelet-rich fibrin membranes (A-PRF, Process For PRF, Nice, France). To prepare the A-PRF 36 ml of autologous venous blood were collected into four tubes (in glass without additives) of 9 ml that were immediately centrifuged at 1300 rpm for 8 minutes. The PRF membranes were placed in the wound and sutured to the surrounding gingiva with 4.0 vicryl suture. Simultaneously injections of PRF in liquid form (i-PRF, Process For PRF, Nice, France) were performed in the site underwent surgery and around fistulas using an insulin syringe. i-PRF was prepared collecting 18 ml of autologous venous blood into two tubes (in plastic without additives) of 9 ml that were immediately centrifuged at 700 rpm for 3 minutes. Antibiotic therapy and i-PRF injections were repeated for two weeks after the surgery. Programmed monitoring of mucosal healing was carried out postoperatively at 7 (when the sutures were removed), 14, 21 days and at 30, 60, and 90 days. Healing process was initially characterized by the reduction of pain and leakage exudate. A complete wound healing was obtained in 4 weeks after the application of PRF membranes. The complete resolution of oro-cutaneous fistulas was observed after two i-PRF injections and there was no noted leakage of exudate from the symphysis area after 3 weeks. After 1 month follow-up, the patient appears clinically free of disease as demonstrated also by clinical absence of necrotic bone in oral cavity, absence of necrotic bone radiological signs, absence of pain and exudate leakage and oro-cutaneous fistulas healing. The patient was followed up for 30 months and there was no recurrence or necrotic bone exposure.

**CONCLUSIONS:** Although the findings in this study may not be conclusive, the combination of surgery and PRF application seems to be useful for the treatment of refractory MRONJ. Preparation simplicity and the low cost of PRF allow to consider this method as an excellent adjunctive tool to improve healing of the tissues in MRONJ patients. This treatment showed great improvement in terms of health status and psychological wellbeing for the patient.

#### REFERENCES:

1. Bedogni, Alberto, *et al.* "Staging of osteonecrosis of the jaw requires computed tomography for accurate definition of the extent of bony disease." *British Journal of Oral and Maxillofacial Surgery* 52.7 (2014): 603-608.
2. Del Fabbro, Massimo, Giorgia Galesio, and Marco Mozzati. "Autologous platelet concentrates for bisphosphonate-related osteonecrosis of the jaw treatment and prevention. A systematic review of the literature." *European Journal of Cancer* 51.1 (2015): 62-74.
3. Maluf, Gustavo, Rogério Jardim Caldas, and Paulo Sérgio Silva Santos. "Use of Leukocyte-and Platelet-Rich Fibrin in the Treatment of Medication-Related Osteonecrosis of the Jaws." *Journal of Oral and Maxillofacial Surgery* 76.1 (2018): 88-96.

## **B02 - Solitary plasmacytoma of the mandible and bisphosphonate: a unique case of re-mineralization**

C.C. Bianchi <sup>1</sup>, F. Esposito <sup>1\*</sup>, F. Erovigni <sup>2</sup>, P. Fonio <sup>1</sup>, S. Carossa <sup>2</sup>

<sup>1</sup>Department of Radiology, University of Turin, Turin, Italy;  
<sup>2</sup>CIR Dental School, University of Turin, Turin, Italy

**BACKGROUND:** Plasmacytoma is a clonal neoplastic disorder of bone marrow originating from plasma cells that

presents with solitary or multiple masses in either bone or soft tissue (ie, extramedullary plasmacytoma). 1 Although any bone might be affected a solitary plasmacytoma of the mandible is an extreme rare entity. Solitary plasmacytoma may be a non-evolving disease albeit the majority of them progresses to multiple myeloma in 2-3 years after diagnosis. While the isolated form has a benign prognosis, 2 cases evolving in multiple myelomas are associated with a severe prognosis. Bone marrow aspirate and/or bone marrow biopsy are normal in solitary plasmacytoma. Therefore, only a direct bone biopsy either radiological or surgical allows the diagnosis of a solitary plasmacytoma. Administration of bisphosphonate (BF) inhibits bone resorption by interfering with the action of osteoclasts after being selectively adsorbed to mineral bone surfaces<sup>3</sup>. As a result a re-mineralization is usually seen in spongy bones while this effect has never been described in osteolytic lesions.

**CASE REPORTS:** A 78-year-old male patient, with a medical history of osteoporosis, presented to the Radiologic Department of the University of Torino in June 2012 for a strong, persistent pain in the mandibular molar region. A panoramic radiograph revealed a defined osteolytic radiolucent area involving the right mandibular angle determining an extreme thinning/loss of the cortical bone. A msCT confirmed the presence of a large osteolytic area, with irregular margins and hypodense content, remodeling and thinning the inferior border of the mandible with a cortical bone erosion. The patient underwent a CT-guided biopsy. The histopathological examination of the specimen revealed a solid proliferation of plasmacytoid cells with eccentric nuclei and basophilic cytoplasm, partially showing atypia on haematoxylin and eosin staining, which was diagnostic of plasmacytoma. A skeletal radiographic survey was then performed showing no additional osteolytic lesion. Therefore, the patient was diagnosed with a solitary plasmacytoma and received a BF treatment in association with Bortezomib, Melphalan and prednisone. The follow-up examination with panoramic radiography and CBCT revealed a progressive, prominent bone re-mineralization of the osteolytic lesion. In April 2016 (4 years later) panoramic radiograph and CBCT demonstrated a complete bone re-mineralization with a global restoration of the cortical bone, especially the vestibular restoration.

**DISCUSSION:** Bisphosphonates are the standard care for management in patients with metastatic lesions associated with multiple myeloma and solid tumor including breast, prostate and lung cancer, and are also used in Paget's disease, osteogenesis imperfecta and osteoporosis. The action mechanism of bisphosphonates consists in the reduction of osteoclast activity resulting in remineralization of spongy bones<sup>3</sup>. Our case presents an extremely rare localization of solitary plasmacytoma that underwent a complete bone re-mineralization of a large osteolytic area, without a spongy bone component, a total restore of the cortical bone and a restoration of a good thickness of the corticals as a results of bisphosphonates treatment. To our knowledge this effect has never been described before.

#### REFERENCES:

1. William JW *et al.* *Hematology*. New York, NY: McGraw Hill, Inc.; 1990:1140-1147
2. Corwin JD *et al.* Solitary plasmacytoma of bone vs extramedullary plasmacytoma and their relationship with multiple myeloma. *Cancer*. 1979;43:1007-1013
3. Bianchi SD, *et al.* Computerized tomographic findings in bisphosphonate-associated osteonecrosis of the jaw in patients with cancer. *Oral Surg Oral Med Oral Pathol Oral Radiol Endod*. 2007;104(2):249-58.

**B03 - MRONJ around fixtures: clinical aspects, treatment and outcome in 6 patients**

F. Erovigni, A. Gambino, I. Bosso \*, A. Dell'Acqua, S. Carossa  
*Department of Surgical Science, Oral Surgery Section, C.I.R. Dental School, University of Turin, Turin, Italy*

**BACKGROUND:** Bisphosphonate-related osteonecrosis of the jaw (BRONJ) is a side effect of long-term bisphosphonate therapy. Marx and Migliorati first described BRONJ in 2003 with a series of case reports. However, osteonecrosis can be associated with other antiresorptive and antiangiogenic therapies, so the American Association of Oral and Maxillofacial Surgeons in the Position Paper of May 2014 proposed the term "Medication-Related Osteonecrosis of the Jaw (MRONJ)", that better describes this condition. Dentoalveolar surgery including tooth extractions and dental implant placement is considered the major risk factor for developing medication-related osteonecrosis of the jaw. Jacobsen and Kwon suggest that also existence of implant itself can be considered a trigger-factor for osteonecrosis. They observed that many patients developed MRONJ without any relation to surgical trauma from implant surgery.

**PURPOSE:** The aim of this study is to describe a case series of MRONJ around or near bone integrated implant fixtures treated in our department of Oral Surgery in Dental School of Turin.

**METHODS:** A retrospective review of six patients who were treated for MRONJ near or around dental implants from 2016 to 2017 in the Department of Oral Surgery was performed. All patients were female with an average age of 60, 17±9.5 years old and they had a history of bisphosphonate or denosumab use. They showed presence of MRONJ near or around dental implants; four patients were affected by stage III lesions, one patient by stage II lesion and two patients presented stage I lesions (SICMF-SIPMO classification 2012). Four patients suffered from cancer and the two patients had osteoporosis. Two patients received intravenous bisphosphonates (zoledronic acid), one patient received oral bisphosphonate (bondronate) and three patients received denosumab. In all patients it was made a full-thickness trapezoidal flap with two vertical incisions from each side, then it was made a periosteal detachment and necrotic bone exposure, sequestrectomy, and ultrasonic bone debridement performed by piezosurgery. We put PRGF in the sequestrectomy site and the flap was sutured in order to obtain a primary closure.

**RESULTS:** After surgery, four patients showed a perfect healing of the site involved; there were no postoperative complications and patients were seen at monthly follow-ups. Only one patient showed recurrence in the same site after two months and it was made a new resection of necrotic bone. In five patients implants were removed. In one case implant was initially preserved, but the patient required a second surgery after three months to eliminate implant and necrotic bone around it.

**CONCLUSIONS:** This case series highlights how the presence of implants can represent a trigger-factor for development of MRONJ also without any relations to surgical trauma. Clinicians have to be aware of the possible risk of jaw necrosis around an osseointegrated dental implant in patients that received BP, other antiresorptive or antiangiogenic therapies.

Strict follow-ups and oral hygiene motivation are mandatory for these patients.

**REFERENCES:**

1. Kwon T-G, Lee C-O, Park J-W, Choi S-Y, Rijal G, Shin H-I. Osteonecrosis associated with dental implants in

patients undergoing bisphosphonate treatment. *Clin. Oral Impl. Res.* 25, 2014, 632–640

2. Ata-Ali J, Ata-Ali F, Pe-narrocha-Oltra D, Galindo-Moreno P., What is the impact of bisphosphonate therapy upon dental implant survival? A systematic review and meta-analysis *Clin. Oral Impl. Res.* 27, 2016, e38–e46
3. Jacobsen C, Metzler P, Ro'ssle M, *et al.* Osteopathology induced by bisphosphonates and dental implants: clinical observations. *Clin Oral Investig* 2013;17:167-175

**B04 - Osteonecrosis of jaw (ONJ) involving maxillary bone initially not recognized by rhinologists: an alert for careful drug history**

F. Canevari \*, A. Fasciolo, L. Benzi, M. Nicolotti, V. Fusco  
*ENT Dept (Rhinology Unit), Maxillofacial Surgery Unit, Radiology Dept. Oncology Unit, and "Centro Documentazione Osteonecrosi", Azienda Ospedaliera "SS. Antonio e Biagio e C. Arrigo", Alessandria, Italy*

**BACKGROUND:** Maxilla bone diseases are usually object of visit in ENT and Rhinology units, as well as in Maxillofacial Surgery units. Maxillary bone ONJ can mimic other diseases and can be not immediately recognized.

**CASE DESCRIPTION:** A 66 year old woman complained of several recurrent maxillary infections between 2014 and 2016; in those years she was submitted to several teeth extractions and implant placements. On July 2016 she was visited in ENT Department and a diagnosis of right maxillary odontogenic sinusitis was made. After an antibiotic therapy course, on July 2016 a FESS (Functional Endoscopic Sinus Surgery) was performed, consisting of right inferior uncinectomy in order to expose maxillary ostium and middle anastomosis widening posteriorly the ostium itself. On August 2016, thirty days after the FESS, she complained again pain and a maxillary Computed Tomography (CT) scan was performed out of hospital. The radiologist reported alterations of right and left maxillary sinus, with maxillary bone defects in sinus walls and also in incisor area. On October 2016, she was visited at a referral Dental Care Department; a careful drug history revealed that she had been treated with alendronate for 14 years (2002-2016) for postmenopausal osteopenia. A new enlarged and refined CT scan showed a huge bone destruction of maxillary bones, nasal plug, maxillary sinus walls; osteosclerosis of remaining maxillary bones till to the right zygomatic region; soft tissue inflammation till to plans under the skin in maxillary and nasal area; a suspected osteosclerotic area in the left side of mandible, next to an implant (out of its natural site). The case (without frank bone exposure) was staged as ONJ (MRONJ) "stage 0" (according to the AAOMS staging system) – stage 2 (according to the SIPMO-SICMF staging system). On November 2016, an exploratory surgical revision was planned; in the meanwhile, a tiny bone fragment was spontaneously ejected from the right maxillary bone through a mucosal break. On January 2017, a surgical sequestrectomy was performed at right maxillary bone, with application of PRP (platelet-rich plasma) derived membrane, and reconstruction with flap. At the following control visits, the patient complained no pain and the mucosa was regular. The patient is now carefully followed due to the risk of maxillary ONJ relapse and of potential incoming mandible ONJ next to implant area.

**DISCUSSION:** ENT specialists and rhinologists have to collect careful drug history in presence of maxillary disease, to

avoid late diagnosis of ONJ. Endoscopic surgical approach to maxillary sinus in ONJ should be considered in selected cases on the basis of radiological findings in order to allow a better healing of the mucosa of the maxillary sinus but never as exclusive procedure.

#### REFERENCES:

1. Ruggiero S. *et al.* American Association of Oral and Maxillofacial Surgeons Position Paper on Medication-Related Osteonecrosis of the Jaw-2014 Update. *J Oral Maxillofac Surg* 2014; 72/10:1938-56
2. Bedogni A, Fusco V, Agrillo A, Campisi G. Learning from experience. Proposal of a refined definition and staging system for bisphosphonate-related osteonecrosis of the jaw (BRONJ). *Oral Dis*. 2012;18(6):621-3.
3. Bedogni A., Campisi G., Agrillo A, Fusco V.. Raccomandazioni clinico-terapeutiche sull'osteonecrosi delle ossa mascellari associata a bisfosfonati e sua prevenzione. Cleup Editore, Padova (2013).

### **B05 - Aggressive Osteonecrosis of the Jaw (BRONJ) due to alendronate therapy: case report**

F. Erovigni, E. Duni\*, A. Gambino, P. Garzino, C. Bianchi

*Department of Surgical Sciences, Oral Surgery Section, CIR-Dental School, University of Turin, Turin, Italy*

**BACKGROUND:** Bisphosphonate-Related Osteonecrosis of the Jaw (BRONJ) is a drug-related adverse reaction that affects the mandibular and / or maxillary bone of patients exposed to treatment with amino-bisphosphonates (BPs), in the absence of other recognizable causes. The incidence of BRONJ varies from 0.8% to 12% in patients receiving intravenous BPs (it depends on the primary pathology for which the indication of bisphosphonate therapy has been given, the general systemic conditions, the dose and the frequency of administration), but there are no significant estimates in patients receiving intramuscular or oral administration.

**CASE PRESENTATION:** 66-year-old patient, history of gastric cancer and gastric resection (1995 and recurrence in 2005), previous intestinal obstruction, cholecystectomy, disc herniation and osteoporosis. In therapy with alendronate since about 2012. The patient came to receive dental visit on July 9th, 2014 because of non-healing of the post-extraction site in 3.8, performed at another location in April of the same year, with intraoral fistula at the post-extraction socket in association with purulent exudates together with pain symptomatology. Radiographic examination (OPT + CT) showed bone rarefaction and signs of bone remodeling at the post-extraction socket. A diagnosis of BRONJ (stage I AAOMS; stage I b SIPMO / SICMF) was made. The patient started an antibiotic therapy with im ceftriaxone, and the surgical revision of the site was scheduled, also using platelet concentrates (PRGF) and repeated sessions of laser therapy (LLLT) to biostimulation and disinfection of the surgical site. On September the patient started a therapy with teriparatide due to its usefulness to cure both osteoporosis and (probably) BRONJ. On October, after a first phase of gradual health improvement, there was a relapse, with enlargement of the osteonecrotic area (as a new CT confirmed); consequently we decided to make a second surgical revision that also included the extraction of the element 3.7, involved in the necrotic area. Like in the first case, the surgery was performed with platelet concentrates (PRGF) and laser therapy (LLLT). After the weight

loss that occurred during this period it was assumed that the current antibiotic therapy wasn't achieving the desired effects. Dietary advice was requested at the Dietology Unit of the Città della Salute e della Scienza of Turin, Hospital S. Giovanni Battista - Molinette and a consultancy at the Osteomyelitis clinic (Amedeo di Savoia Hospital) in order to identify the most effective antibiotic therapy. On December, because of the continuous weight loss, the patient was admitted to the Department of Internal Medicine for weight recovery. She was later transferred to the Maxillofacial Surgery department, where she underwent hemimandibulectomy. Following infection of the osteosynthesis plate a second operation was performed, in which it was replaced with a second plate. It was also performed root canal treatment of 3.6.

**CONCLUSIONS:** The patient remained under strict clinical and radiographic control and no recovery of necrosis occurred. Where segmentation of the mandible was performed a bone stump was formed, probably from the residual periosteum. This was stabilized in a third operation (2016).

**DISCUSSION:** To notice the peculiar aggressiveness of the osteonecrotic event in a patient considered to be at low ONJ risk (2 years of alendronate therapy) and not responsive to pharmacological therapies. Another element worthy of discussion is the new bone formation 3 years after the development of necrosis.

#### REFERENCES:

1. Bedogni A, Fusco V, Agrillo A, Campisi G. Learning from experience. Proposal of a refined definition and staging system for bisphosphonate-related osteonecrosis of the jaw (BRONJ).

### **B06 - Denosumab treatment after femur fracture: lights and shadows. A case report**

A. Fasciolo\*, L. Benzi, I. De Martino, M. Alessio, V. Fusco

*Maxillofacial Surgery Unit, Radiology Dept., Oncology Unit, and "Centro Documentazione Osteonecrosi", Azienda Ospedaliera "SS. Antonio e Biagio e C. Arrigo", Alessandria, Italy*

**BACKGROUND:** Bisphosphonates (BP) and denosumab are antiresorptive agents largely prescribed to prevent skeletal fractures in patients at risk (osteoporosis and Rheumatoid Arthritis) and in all patients already suffering from fractures (to avoid other events). Osteonecrosis of Jaws (ONJ) related to BPs or denosumab is a concern for all these patients. Treatments determining ONJ risk and proposed for prevention and/or treatment of osteoporosis and its complication (i.e. fractures) include: oral alendronate (70 mg/week); oral risedronate (35 mg/week); iv ibandronate (3 mg q3months); oral ibandronate (150 mg monthly); yearly iv zoledronic acid (5 mg q12months); sc denosumab (60 mg q6months). All these agents showed possible induction of ONJ, described by some Authors as "rare" (1/1.000-1/10.000, according to WHO) or "very rare" (<1/10.000)(Adler *et al.* 2016), usually after years of treatment. Actually, evaluations about the individual ONJ risk are uncertain, due to bias in old trials (unknown ONJ; short-term follow-up; etc) and in recent trials (very restricted ONJ definition; limited observation time). Vice versa, real life ONJ cases after BPs and/or denosumab treatment in osteoporosis patients are not so rare (even if probably underdiagnosed), exceeding the ONJ cases in metastatic cancer patients in some countries.

**CASE DESCRIPTION:** A 85 year old woman complained of several recurrent left hemi-mandible infections on 2015, with areas of fistula / mucosal break, submitted to curettages

by her dental practitioner. On November 2015 she was visited in Maxillofacial Surgery Department due to intermittent pus discharge and a persistent fistula in lingual side of left hemi-mandible, without pain. Clinical and drug history revealed that on 2012 the woman suffered from a traumatic (car accident) femur fracture and she started subcutaneous denosumab (60 mg every six months) to prevent other fractures. Previously she had been under anti-osteoporosis treatment with D vitamin, but she never received BPs. At that time a clinical diagnosis of left mandible denosumab-related ONJ was made (stage 0 according to 2009 AAOMS staging system and stage I-II according to 2014 AAOMS modification). A Computed Tomography (CT scan) was requested and it showed a large destruction of left side of mandible, deep next to the mandible canal (stage IIa-IIb according to the SICMF-SIPMO staging system). After an antibiotic therapy course, on February 2016, pros and cons of a surgical sequestrectomy were discussed with the patient and her family; the patient preferred to avoid the surgery, at the moment. The patient was then carefully followed for two years: neither severe infections nor spontaneous expulsion of bone were observed.

**DISCUSSION:** Denosumab decreases the risk of fracture, or of second event after a fracture. Denosumab-related ONJ occurred in this case less than three years after start of treatment (ONJ is usually diagnosed after 3-5 years of BPs at common doses/schedules in osteoporotic patients). In elderly patients, the choice of surgical *versus* conservative strategy can be limited by age, other disease, attitude of patient and caregivers. However, also a conservative strategy, even in absence of spontaneous expulsion of sequestrum, can be useful.

#### REFERENCES:

1. Adler RA *et al.* Managing osteoporosis in patients on long-term BP treatment: report of a Task Force of the ASBMR, *J Bone Miner Res.* 2016 Jan;31(1):16-35
2. Bedogni A, Fusco V, Agrillo A, Campisi G. Learning from experience. Proposal of a refined definition and staging system for bisphosphonate-related osteonecrosis of the jaw (BRONJ). *Oral Dis.* 2012;18(6):621-3.
3. A. Bedogni, G. Campisi, A. Agrillo, V. Fusco. Raccomandazioni clinico-terapeutiche sull'osteonecrosi delle ossa mascellari associata a bisfosfonati e sua prevenzione. Cleup Editore, Padova (2013). Available at [www.sipmo.it](http://www.sipmo.it)

### **B07 - Platelet Rich Fibrin (PRF) Vivostat as a possible alternative for MRONJ treatment: a case report**

L. Feraboli\*, F. Bolognesi, A. Tarsitano, A. Pizzigallo, C. Marchetti

*Unit of Oral and Maxillofacial Surgery, Department of Biomedical and Neuromotor Science (DIBINEM), Alma Mater Studiorum - University of Bologna, Bologna, Italy*

Medication-related osteonecrosis of the jaw (MRONJ) is a severe adverse drug reaction, consisting of progressive bone destruction in the maxillofacial region of patients. ONJ can be caused by either antiresorptive or antiangiogenic drugs but its pathophysiology has not been completely elucidated. For this reason, its treatment is still controversial and based on two main possible approaches: a non-surgical one, that usually uses antimicrobial agents and minimal debride-

ment but it's not sufficient to control the overinfection of the necrotic bone and its related symptoms, and a surgical one, reserved for more advanced cases of MRONJ (stage III). The usage of platelet concentrates in the surgical cases of MRONJ has been suggested for the first time by Marx in 1998. The first one to analyse the results obtained with platelet concentrates was Adornato in 2007. Since then, several other authors have studied the efficacy of platelet concentrates as a supplement to surgery: Rupel *et al.* (1) have highlighted how higher rates of treatment success are achievable with the use of platelet concentrates during surgery, while Del Fabbro *et al.* (2) report a 91,6% of success in patients treated with platelet concentrates vs an 85% of success in patients treated with surgery only. Platelet-Rich Fibrin (PRF) is a second generation platelet concentrate whose use has been proposed in different surgical procedures in order to ameliorate wound healing. Vivostat Platelet Rich Fibrin (PRF) is an automated, closed and sterile system used for the preparation of platelet rich fibrin from homologous whole blood. The platelet concentration that you obtain with this system is ten times higher than the basal level and with a fibrin concentration around 18.1 ng/ml (3). Through the process towards the final PRF product, homologous whole blood from the patient undergoes several both mechanical (spinning) and biochemical steps (addition of anticoagulant citrate, Tranexamic acid, Batroxobin and buffers (acetate + bicarbonate)). We present a case of a patient who developed a post-extraction osteonecrosis of the mandible related to Zoledronic acid administration for bone metastasis treatment of lung adenocarcinoma. We performed a segmental resection of the mandible preserving the inferior alveolar nerve and then placed the PRF fibrin glue onto the residual bone and obtained the closure of the overlying oral mucosa by primary intention, using resorbable stitches. Finally, we layered the wound with an additional film of PRF. The post-surgical course has been regular and characterized by complete healing of the surgical wound, with pain, inflammation and purulent secretion regression. In conclusion we think that PRF could be a valuable and alternative strategy for the treatment of MRONJ.

#### REFERENCES

1. Del Fabbro *et al.* Autologous platelet concentrates for bisphosphonate-related osteonecrosis of the jaw treatment and prevention. A systematic review of the literature. *Eur J Cancer* 51: 62e74, 2015
2. Rupel K. *et al.* A systematic review of therapeutical approaches in bisphosphonates-related osteonecrosis of the jaw (BRONJ). *Oral Oncol* 50: 1049e1057, 2014.
3. Alternative treatments for oral bisphosphonate-related osteonecrosis of the jaws: A pilot study comparing fibrin rich in growth factors and teriparatide. A. Pelaz *et al.* *Med Oral Patol Oral Cir Bucal.* 2014 Jul 1;19 (4):e320-6.

### **B08 - Oral bisphosphonate-related mandible ONJ: an underestimated issue? A report of five different cases**

B.Fornaca<sup>1</sup>\*, L.Basano<sup>1</sup>, U.Gibello<sup>1</sup>, A.Codegone<sup>2</sup>, P. Appendino<sup>1</sup>

<sup>1</sup>Dentistry and Oral Surgery Department, Turin, Italy; <sup>2</sup>Nuclear Medicine Department, Mauriziano Hospital, Turin, Italy

**BACKGROUND:** Oral bisphosphonates are drugs largely utilized for the treatment of the osteoporosis.

The extensive supply along with the low incidence of contraindications may cause both the reduction to the threshold of the attention of dentists and a low attitude of the patients in addressing themselves to the dentist. In addition, as of today, the patients in therapy with bisphosphonates for osteoporosis are not part of a plural-specialists network which should thoroughly supervise and control the overall conditions of the patient's mouth during those periods of therapy (as specifically indicated to those receiving bisphosphonates due to cancer diseases). On 2017 at our Surgical Division, out of 12 different cases surgically treated for MRONJ (Medication related osteonecrosis of the jaws) in narcosis, seven patients were in therapy with intravenous bisphosphonates, whereas five other patients were in therapy with oral bisphosphonates for osteoporosis. All of these cases are being classified under the A.A.O.M.S. and S.I.C.M.F.-S.I.P.M.O. staging criteria.

**AIM OF THE STUDY:** The aim of this study is to describe in details these 5 different cases (5 ♀, average age 81,4) of osteonecrosis of the jaw, based on the type of molecule (3 alendronic acid, 1 alendronic acid + risendronic acid and 1 ibandronic acid), time of consumption (>4 years), triggering event (extractions and prosthesis decubitus), simultaneous morbidities; finally, all classified by AAOMS and SICMF-SIPMO criteria. All of the 5 above mentioned cases are the direct result of dental operations. It is relevant to say that 2 of these patients didn't report to the dentist about their own therapy with oral bisphosphonates. Cases in stage  $\geq 2b$  have all submitted to bone resection surgery in narcosis. Upon full recovery at both oral and radiographic healing, they have been included in a follow-up program.

**CONCLUSIONS:** Although according to the literature the incidence of osteonecrosis of the jaw for these kind of patients is equal to 1/100000, it is also acknowledged that the accumulation of this drug is related to the length itself of assumption of the oral bisphosphonates for many years. In conclusion, we believe to be crucial to establish a "procedure of awareness" through a synchronized collaboration of all specialists to achieve a pristine and safe coordination between Health Public Departments and patients themselves.

#### REFERENCES:

1. Ruggiero SL *et al.* American Association of oral and maxillofacial surgeons position paper on bisphosphonate-related osteonecrosis of the jaws – 2009 update. *J Oral Maxillofac Surg* 67(5 Suppl): 2–12.
2. Aljihoani S. *et al.* What is the effect of anti-resorptive drugs (ARDs) on the development of medication-related osteonecrosis of the jaw (MRONJ) in osteoporosis patients: A systematic review *Journal of Cranio-Maxillo-Facial Surgery* 45 (2017) 1493e1502
3. Migliorati CA *et al.* How patients' lack of knowledge about oral bisphosphonates can interfere with medical and dental care. *J Am Dent Assoc.* 2010 May;141(5):562-6.

### B09 - Multifocal MRONJ: a report of six cases

F. Erovigni, A. Gambino, V. Gallo\*, M. Carossa, A. Dell'Acqua  
*Università di Torino, CIR Dental School, Turin, Italy*

**BACKGROUND:** MRONJ can occur in some patients in a particularly severe manner, with the development of multiple lesions in different areas of the jaws. There is a lack of literature about this kind of manifestation.

**AIM:** To review clinical cases of patients affected by multifocal

MRONJ, as opposed to the more common manifestation of single site MRONJ.

**CASE REPORTS:** Case 1: A 73 years old man affected by lung cancer with bone metastases. He underwent zoledronate therapy from 2/2014 to 6/2014 and denosumab from 8/2014 to 1/2015. MRONJ stage II was diagnosed in region 4.5-4.6 on 2/2015, treated with osteoplasty without achieving complete healing. The second lesion, stage II, appeared in region 3.7 on 10/2015. The patient never restarted antiresorptive therapy after the first ONJ diagnosis.

Case 2: A 71 years old woman affected by osteoporosis. She began alendronate therapy from 2007; she was first diagnosed with MRONJ stage III in region 3.1-3.2 on 10/2016. The patient restarted the oral BP on 1/2017. The second lesion appeared in region 2.4-2.5, stage I, on 06/2017 and resolved after LLLT.

Case 3: A 66 years old woman affected by breast cancer with bone metastases. She began zoledronic acid therapy on 08/2009; she was first diagnosed with MRONJ (stage II) in region 4.8 on 07/2010 and healed after sequestrectomy. On 7/2015 she started therapy with Denosumab. The second lesion appeared as stage II MRONJ in region 4.3 on 09/2017. After bone debridement and LLLT a complete re-epithelization of the bone occurred.

Case 4: A 79 years old woman affected by breast cancer with bone metastases. She began risendronic acid therapy on 2007, then switched to zoledronate therapy from 9/2009 to 3/2014. Bilateral MRONJ in regions 1.7 (stage II) and 2.7 (stage III) were first diagnosed on 10/2015, treated with sequestrectomy. The third lesion (stage II) occurred in region 3.5 on 12/2017, and healed after bone sequestrectomy.

Case 5: 76 years old man affected by multiple myeloma. He began zoledronic acid therapy on 04/2011; stage I MRONJ was first diagnosed in region 4.8 on 12/2015, which healed after piezosurgery, osteoplasty and antibiotics. The second lesion appeared in region 3.8 on 04/2016 and resolved spontaneously after LLLT. A third lesion appeared on 1/2017 in region 4.6 (oral fistula). The patient is currently asymptomatic and in follow-up. He restarted zoledronic acid after the resolution of the first MRONJ, but suspended the therapy after the second one.

Case 6: 69 years old woman affected by breast cancer with bone metastases. She began zoledronic acid therapy on 03/2009; was first diagnosed with MRONJ on 10/2015 in region 1.7-1.8 (stage III); the second lesion (stage II) appeared in region 3.3-3.4 on 02/2016. The maxilla lesion healed after sequestrectomy, while the mandibular one didn't. The patient dropped out from follow up in 6/2016.

**CONCLUSIONS:** We can observe how in all reported patients the multiple lesions appear either in mandible or in both maxilla and mandible; this is in accordance with the current literature data, which reports that MRONJ is more likely to appear in the mandible (73%) than in the maxilla (22.5%). Multifocal MRONJ appears to be present in both cancer and osteoporotic patients. The occurrence of multiple lesions suggests the possibility of a greater susceptibility to MRONJ in certain groups of patients, but further studies are required to investigate this subject.

#### REFERENCES:

1. Ruggiero SL, Dodson TB, Fantasia J, Goodday R, Aghaloo T, Mehrotra B, *et al.* American Association of Oral and Maxillofacial Surgeons position paper on medication related osteonecrosis of the jaw--2014 update. *J Oral Maxillofac Surg Off J Am Assoc Oral Maxillofac Surg.* 2014 Oct;72(10):1938-56

## B10 - An unusual case of osteonecrosis of the jaw in a renal cell carcinoma patient treated with sunitinib alone

E. Gaudino <sup>1\*</sup>, A. Fasciolo <sup>2</sup>, C. Loddo <sup>1</sup>, V. Fusco <sup>3</sup>, G. Vellani <sup>1</sup>

<sup>1</sup>Oncology Unit ASL TO4, Ospedale Civile di Ivrea, Ivrea, Italy; <sup>2</sup>Maxillofacial Surgery Unit, Alessandria, Italy; <sup>3</sup>Oncology Unit, ASO Santi Antonio e Biagio e Cesare Arrigo di Alessandria, Alessandria, Italy

**BACKGROUND:** Osteonecrosis of the jaw (ONJ) is often a quality-of-life-lowering condition described as a bone infarction due to ischemia, which occurs in patients treated with bisphosphonates (BPs) and anticancer agents. Sunitinib is linked to most of TKI-related ONJ cases, with or without BP therapy. We reported a case of ONJ with renal cell carcinoma (RCC) under sunitinib medication without history of oral surgery and BP therapy.

**CASE REPORT:** The report is about a 64-year-old man, treated with sunitinib between 2011 and 2017 for lung metastases from RCC. He underwent left nephrectomy on March 2009; from January 2011 to November 2013 he received 35 cycles of 50 mg sunitinib once a day for 4 weeks followed by 2 weeks drug free with radiological complete response. At November 2013 he was on "drug holiday". The patient had dental implants since 2010; neither mandibular pain nor bone or mucosal lesions were present at the time of sunitinib start. Since 2013, the patient presented continuous oral mandibular pain and dental abscesses needing repeated antibiotic cycles, with benefit during week off from sunitinib; the first diagnosis was perimplantitis. On April 2014 patient resumed sunitinib due to pulmonary progression of RCC with a contemporary worsening of oral disease. The patient was referred to the ONJ Multidisciplinary Team at Alessandria Hospital, and submitted to panoramic radiograph and dental tomography (CT) scans between April and June 2014. Imaging showed bilateral mandibular bone resorption and right lower bone fixture with osteolytic area at the right hemimandible (around 22 x 11 mm), with subsequent diagnosis of perimplantitis / ONJ "stage 0" (according to AAOMS staging system), or stage 1 (according to SIPMO-SICMF definition and staging system). He repeated CT scans and a bone scintigraphy was performed on 2015, showing uptake in right hemimandible (with less evident at left side). CT scan alterations and bone scan right mandible uptake were confirmed on 2016. The patient received conservative therapy until 2017 October, when he was submitted to remove of lower right dental implant, mobile at that time. He terminated sunitinib on July 2017 due to further pulmonary progression of RCC.

**DISCUSSION:** Sunitinib is an oral TKI, approved for advanced RCC, that inhibits vascular endothelial growth factor and platelet-derived growth factor receptors. Literature reported that sunitinib might increase the risk of BP-induced ONJ or worsen it. Mechanisms involved in ONJ induced by antiangiogenic drugs is inhibition in jawbone remodelling, wound repairing and soft-tissue damage. In a recent Danish cohort of 204 consecutive patients with ONJ were detected 7 cases of MRONJ associated with TT (3.4%): four patients received TT only, whereas 3 were concomitantly treated with BPs and/or denosumab. Felssing *et al.* reported a 58-year-old woman under sunitinib treatment who developed ONJ, after no BPs or corticosteroids. Other Authors report ONJ onset correlate to contemporary therapy with TKIs and BPs. In our case the patient was never treated with BPs and had no history of oral surgery during sunitinib treatment. ONJ persisted during a drug holiday period without evident disease progres-

sion and the mandible radiological lesions could be correctly evaluated (no metastases). Oral condition got worse when patient resumed sunitinib. In conclusion, our case was a real sunitinib-related ONJ. We choose to not discontinue sunitinib because of disease control of RCC; multidisciplinary collaboration between Oncology and Oral Surgery units allowed the patient to receive efficient anticancer treatment and oral conservative therapy for a long time.

### REFERENCES:

1. Fusco V, Santini D, Armento G, Tonini G, Campisi G. Osteonecrosis of jaw beyond antiresorptive (bone-targeted) agents: New horizons in oncology. *Expert Opin Drug Saf.* 2016;15:925–35.
2. Beuselink B, Wolter P, Karadimou A, Elaidi R, Dumez H, Rogiers A, *et al.* Concomitant oral tyrosine kinase inhibitors and bisphosphonates in advanced renal cell carcinoma with bone metastases. *Br J Cancer.* 2012;107:1665–71
3. Abel MM, Nielsen CEN, Schiodt M. Medication related osteonecrosis of the jaws associated with targeted therapy as monotherapy and in combination with antiresorptives. A report of 7 cases from the Copenhagen Cohort. *Oral Surg Oral Med Oral Pathol Oral Radiol.* 2018 Feb;125(2):157-163.

## B11 - Er:YAG laser for bone vaporization and Auto-Fluorescence as a guide in highlighting surgical margins: a new surgical approach

I. Giovannacci <sup>1,2</sup>, C. Magnoni <sup>2</sup>, G. Ghidini <sup>1\*</sup>, M. Meleti <sup>1</sup>, P. Vescovi <sup>1</sup>

<sup>1</sup>Oral Medicine and Oral Surgery Laser Unit, University Center of Dentistry, Department of Medicine and Surgery, University of Parma, Parma, Italy; <sup>2</sup>Department of Dermatology, University of Modena and Reggio Emilia, Modena, Italy

**BACKGROUND:** The precise identification of necrotic bone margins during osteonecrosis removal is a major difficulty for surgeons and it is usually based on subjective parameters such as bleeding, colour and texture of the bone. Ristow suggested that also in the absence of tetracycline labelling, vital bone could be highlighted on the basis of its strong Auto-Fluorescence (AF) whereas necrotic bone lost such an AF appearing very dark. The normal AF of collagen, elastin and other fibers in human tissue was observed and described at the beginning of the last century. The molecular sources of this phenomenon are specific amino acids of the collagen molecules, showing AF when irradiated by ultraviolet/blue light. The use of AF as an intra-operative diagnostic tool is used from several years in other medical fields such as inter-vertebral disc surgery. Hoell *et al.* reported that healthy endplates could be clearly identified as hyper-fluorescent, whereas traumatized and degenerated disc appear very dark.

**AIM:** To describe a new surgical approach for Medication Related Osteonecrosis of the Jaw (MRONJ) that couples the advantages of the Erbium (Er):YAG laser and the usefulness of the AF in highlighting surgical margins.

**CASE REPORTS:** A patient affected with mandibular stage II osteonecrosis was treated through this surgical approach.

Histopathological evaluation of non-fluorescent bone and hyper-fluorescent surrounding bone was also performed in order to establish a more accurate correlation between fluorescence and bone vitality. Surgical treatment, consisting in the resection of necrotic bone, was performed under local anaesthesia and without preoperative tetracycline labelling. After bone exposure, VELscope™ system (LED Medical



Diagnostics Inc., Barnaby, Canada) was used to induce and visualize bone AF. Necrotic bone showed no or only pale AF. After removal of necrotic bone block AF was used to guide marginal osteoplasty. According to the AF image obtained after osteoplasty, Er:YAG laser (Fidelis Plus®, Fotona - Slovenia) (Parameters: 300 mJ, 30 Hz, fluence of 60 J/cm<sup>2</sup>) was used for evaporation of necrotic bone. It produces microspots stimulating vascularization and attachment of soft tissues. Er:YAG laser is very useful for further removal of bone after osteoplasty. Because of the very superficial penetration of this device, it is possible to act in the areas where non-fluorescence or hypo-fluorescence is displayed. Further samples of hyper-fluorescent bone were taken in the adjacent areas. Histopathological evaluation was carried out in order to investigate if a correlation between bone vitality and fluorescence exists.

**RESULTS:** Histopathological analysis revealed necrotic tissue in the hypo-fluorescent bone block removed and vital bone tissue in the hyper-fluorescent specimens.

**CONCLUSIONS:** After 36 months follow-up no signs of osteonecrosis were detected. Taking into account technical and biological advantages associated with the Er:YAG laser and the effectiveness of AF in highlighting surgical margins, this approach would probably allow to achieve excellent outcomes.

**REFERENCES:**

1. Ristow O, Pautke C., Auto-fluorescence of the bone and its use for delineation of bone necrosis., *Int J Oral Maxillofac Surg.* 2014 Nov;43(11):1391-3.
2. Hoell T, Huschak G, Beier A, Hüttmann G, Minkus Y, Holzhausen HJ *et al.* Auto fluorescence of intervertebral disc tissue: a new diagnostic tool. *Eur Spine J.* 2006 Aug;15 Suppl 3:S345-53.
3. Giovannacci I, Meleti M, Corradi D, Vescevi P., Clinical Differences in Autofluorescence Between Viable and Nonvital Bone: A Case Report With Histopathologic Evaluation Performed on Medication-Related Osteonecrosis of the Jaws., *J Oral Maxillofac Surg.* 2016 Dec 15. pii: S0278-2391(16)31249-6.

**B12 - Stage III Medication-Related Osteonecrosis in patients treated with oral-bisphosphonate: 4 case reports**

F. Erovigni, A. Gambino, C. Giarracca\*, E. Duni, C. Bianchi, S. Carossa

*CIR Dental School-Università degli Studi di Torino, Turin, Italy*

**BACKGROUND:** The study describes 4 patients with osteoporosis who developed severe MRONJ (stage III according to SIPMO/SICMF) from Alendronate or Ibadronate therapy. BRONJ incidence for osteoporosis is estimated to be between 0,0004% and 0,06% , and the risk increases exponentially if the therapy lasts more than 3 years.

Patient 1) P.R. 71-year-old woman, affected from osteoporosis, came in Oral Surgery Department of Turin Dental School, due to bone exposure in correspondence of a fixture in region 1.6. She had taken on Ibadronate for 4 years. OPT and TC x-rays evidenced an inflammatory aspect of the right maxillary sinus and an area of osteolysis in regions 1.6 and 1.5. Surgical resection was performed, but an intra-oral fistula recurred at 6 months from the surgery. After a new bone debridement, the resolution was complete. The patient is still in follow up with no signs or symptoms of BRONJ.

Patient 2) I.R. A 66-year-old woman affected from osteoporosis, rheumatoid arthritis, atrial fibrillation, thrombosis, arterial hypertension, and dyslipidemia and in therapy with oral bisphosphonates (Alendronate) for about 10 years. Clinically she showed bone exposure in region 4.5, paresthesia of the right inferior lip and mobility of both the exposed bone fragment and the element 4.4. She reported that she underwent to 4.5 extraction. OPT and CBCT showed a pathological fracture. The patient underwent to bone sequestrectomy and stabilization of the two mandibular abutments by osteosynthesis plates.

Patient 3) M.E. A 90-year-old woman with severe osteoporosis, and also hypertensive cardiomyopathy, mitral fibrosis, dyspnea, esophagitis, and sideropenic anemia, arrived in our department in September 2012 with a widespread osteonecrosis on the right side of the jaw with a cutaneous fistula, reported paresthesia of the chin and the right lip. The patient had taken Alendronate for 7 years. Theriparatide therapy was prescribed in order to counteract both BRONJ and osteoporosis. After three months of therapy, the patient showed a complete recovery of the jaw mucosa. Unfortunately, the fistula in the cheek did not resolve. TC evidenced a bone sequestrum stored inside the jaw without the possibility of finding a way out. The patient dropped out few month later.

Patient 4) F.M. A 56-year-old woman, suffering from severe malnutrition caused by anorexia nervosa from an early age. The patient had taken Alendronate for 9 years, for severe osteoporosis. She referred extraction of 2.3, the subsequent bone exposure and surgical review of the site by her dentist without healing. Clinically there was bone exposure with purulent exudate. TC showed an inflammatory reaction in the nasal mucosa. Antibiotic therapy was useful in discontinuing pus formation. At the moment the patient is waiting to program the surgical removal of BRONJ.

**CONCLUSIONS:** Severe BRONJ can occur even in patients treated with oral bisphosphonate. It is necessary to highlight how, maybe due to the underestimation of the BRONJ risk in patients with metabolic disorders and the consequent diagnostic delay, severe MRONJ can also arise in patients who take oral BPH. 3 of the 4 patients described presented comorbidity; which suggests the need for careful dental monitoring in patients with polymorbidity whose take oral BPH. It's necessary to make dentists and general practitioners more aware of the need to carry out an effective medical history and periodic dental checks in patients treated with long-standing BF for oral administration.

**REFERENCES:**

1. American association of Oral and Maxillofacial Surgeons. Position Paper of bisphosphonate-related of the Jaw. 2009.

**B13 - Bilateral maxillary MRONJ triggered by removable denture**

L. Giordano\*, M. Val, M. Berrone, R. Marino, M. Pentenero  
*University of Turin, Department of Oncology, Unit of Oral Medicine and Oral Oncology, Turin, Italy*

Medication-related osteonecrosis of the jaw (MRONJ) is a serious side-effect of treatment with anti-resorptive medications. MRONJ is much more common in patients receiving bisphosphonates for cancer-related skeletal events than in patients treated for non-malignant diseases. Key factors for the development of MRONJ are the type and dose of bisphosphonate, an history of trauma, dental surgery or dental infection. Trauma induced by poor fitting or even adequate removable

dentures can lead to chronic irritation to gingiva and to the underlying alveolar bone and may trigger osteonecrosis. (1) Maxillary sinusitis and oro-antral fistulae are associated with MRONJ in approximately 4% of cases.

**CASE REPORT:** A 57 years old man, affected by prostatic adenocarcinoma with bone secondary involvement, was referred to the Oral Medicine and Oral Oncology department on June 2013 to have an oral evaluation before starting intravenous therapy with Zoledronic Acid (ZA). On examination, the upper maxilla was edentulous and the patient had an adequate rehabilitation with removable denture. In mandible, multiple caries were observed: 4.5 was extracted, while fillings were scheduled for the other decayed teeth (3.2, 3.4 and 4.4). ZA treatment (infusions every 28 days) started six weeks after the extraction. On April 2014, coronal fractures appeared on elements 3.4 and 4.4 requiring extractions which were performed under ZA drug-holiday and antibiotic prophylaxis with amoxicillin+clavulanic acid 875+125mg and metronidazole 500mg, (both 3 times per day starting 3 days before surgery until 10 days after extractions). One month after healing's completion (8 weeks after extractions), treatment with ZA was resumed. On January 2015 the patient complained pain and instability of the upper denture. Clinical examination revealed bilateral extensive bone exposure of the maxillary tuber, most likely related to prosthetic trauma. A computed tomography highlighted a bilateral involvement of the maxillary sinus floor, with a frame of sinusitis of the left sinus (stage 2a MRONJ on the right side, stage 3 MRONJ on the left side). Under general anaesthesia, the necrotic bone was removed resulting in an oro-antral communication of the left side. A pedicled flap was performed with Bichat's buccal fat pad to reinforce a first-intention mucosal closure. A complete clinical healing was obtained; clinical and imaging follow-up at 1, 3 and 9 months ruled out any relapse of osteonecrosis. Even minor trauma, such as intubation and impression tray lesions, precipitated ONJ in a few cases (1%). (2) Wearing removable denture, even if adequate, could well represent a minor trauma to alveolar bone potentially inducing ONJ. In case of ONJ resulting in oro-antral communication, a local pedicled flap as the Bichat's buccal fat flap, is a safe and effective surgical procedure. (3) It provides a good vascularization of the surgical site, protection from possible dehiscence of the mucosal flap and finally Bichat's buccal fat is rich in stem cells useful for tissue regeneration. Bichat's buccal fat flap can be considered a handling technique for the management of bone defects of the posterior maxilla in the case of MRONJ.

#### REFERENCES:

1. Kyrgidis. A, Vahtesevanos K, Koloutsos G, Andreadis C, Boukovinas I, Teleioudis, Patrikidou A, Triaridis S. Bisphosphonate-related osteonecrosis of the jaws: a case-control study of risk factors in breast cancer patients. *J Clin Oncol* 2008 Oct 1;26(28):4634-8
2. Yazdi PM, Shiodt M. Dentoalveolar trauma and minor trauma as precipitating factors for medication-related osteonecrosis of the jaw (ONJ): a retrospective study of 149 consecutive patients from the Copenhagen ONJ Cohort. *Oral Surg, Oral Med Oral Patol Oral Radiol* 2015 Apr;119(4):416-22.
3. Berrone M, Florindi F, Carbone V, Aldiano C, Pentenero M. Stage 3 Medication-Related Osteonecrosis of the Posterior Maxilla: Surgical Treatment Using a Pedicled Buccal Fat Pad Flap: Case Reports. *J Oral Maxillofacial Surgery* 2015 Nov;73(11):2082-6.

## **B14 - Bisphosphonate-associated osteonecrosis of the jaw after short therapy with alendronate: diagnosis and treatment**

R. Ippolito\*, L. Sardelli, R. Parrulli, F. Pavanelli, C. Marchetti  
*Unit of Oral and Maxillofacial Surgery, Department of Biomedical and Neuromotor Science (DIBINEM), Alma Mater Studiorum, University of Bologna, Bologna, Italy*

The "American association of Oral and Maxillofacial Surgeons position paper on bisphosphonate-related osteonecrosis of the jaws" indicates the incidence of osteonecrosis of the jaw (ONJ) by oral therapy with bisphosphonate around 0,01-0,04%. However, considering the past diagnostic delays and, moreover, the recent recognition of the pathology, these figures are an underestimation of the problem. Marx *et al.* in 2003 first described bisphosphonate-related osteonecrosis of the jaw (BRONJ). Later, this pathology was investigated by other clinicians and described as an - adverse reaction manifested in the patient in current or previous treatment with anti-resorptive and/or antiangiogenic agents; that exposed bone or bone that can be probed through an intraoral or extraoral fistula in the maxillofacial region that has persisted for more than eight weeks and no history of radiation therapy or obvious metastatic disease to the jaws. (1) Since ONJ is a multifactorial disease, it is difficult to develop an aetiological therapy. Several studies have identified numerous potential risk factors like dentoalveolar trauma, use of denture, low oral hygiene, endodontic and periodontal infection, diabetes, and steroids. ONJ management is controversial. Rupel *et al.* indicate three different surgical approaches based on the staging of the pathology: conservative surgery, extensive surgery, and laser surgery. (2) An early diagnosis consequently an early stage will create good conditions for a conservative surgical approach to produce good results. In this abstract we present a case of osteonecrosis in a post-menopausal woman treated with alendronate and vitamin D for osteoporotic disease for 3 years. Due to the presence of odontogenic infections, multiple tooth extractions in maxilla and mandibular areas were performed by her private practitioner on April 2017. Considering the permanence of the symptomatology and bone probing after six months, we have diagnosed the presence of necrotic bone in the post extraction site of the upper second premolar. Subsequently, we have treated the patient with surgical conservative therapy associated with administration of antibiotic and local application of disinfectants. Follow up after 3 months revealed complete healing of the treated site and absence of pain and other symptoms. Curiously, the patient reports pain in lower incisal area, one year after the extraction of the second lower incisor. Indeed, it was possible to detect a bone probing and presence of exudate, signs of bone osteonecrosis. Is it an onset of new osteonecrosis or they are the resultant of previous misdiagnosis?

#### REFERENCES:

1. Ruggiero SL, Dodson TB, Fantasia J, Goodday R, Aghaloo T, Mehrotra B, O'Ryan F; American Association of Oral and Maxillofacial Surgeons. American Association of Oral and Maxillofacial Surgeons position paper on medication-related osteonecrosis of the jaw--2014 update. (2014) *J Oral Maxillofac Surg.* 72(10):1938-56.
2. Rupel K, Ottaviani G, Gobbo M, Contardo L, Tirelli G, Vescovi P, Di Lenarda R, Biasotto M. A systematic review of therapeutical approaches in bisphosphonates-related osteonecrosis of the jaw (BRONJ). (2014) *Oral Oncol.* Nov;50(11):1049-57.

3. Otto S, Ristow O, Pache C, Troeltzsch M, Fliefel R, Ehrenfeld M, Pautke C. Fluorescence-guided surgery for the treatment of medication-related osteonecrosis of the jaw: A prospective cohort study. (2016) *Journal of Cranio-Maxillo-Facial Surgery* 44

### **B15 - Surgical treatment of medication-related osteonecrosis of the jaws with addiction of L-PRF: preliminary results**

R. Mauceri\*<sup>1,2</sup>, V. Panzarella<sup>1</sup>, G. Troiano<sup>3</sup>, O. Di Fede<sup>1</sup>, G. Campisi<sup>1,2</sup>

<sup>1</sup>Dept. of Surgical, Oncological and Oral Sciences, University of Palermo, Palermo, Italy; <sup>2</sup>Oral Medicine and Dentistry for patients with special needs, Department of Sensorineural and Motor Surgery, AUOP "P. Giaccone" of Palermo, Palermo, Italy; <sup>3</sup>Dept. of Clinical and Experimental Medicine, University of Foggia, Foggia, Italy

**BACKGROUND:** Main goals of the osteonecrosis of the jaw (ONJ) treatments is to reduce pain, to control infection and to slow the progression of the disease or, when it is achievable, to have a complete healing, eradicating the necrotic bone and, so, the infection<sup>1,2</sup>. Many authors suggested that autologous platelet concentrates, such Leukocyte-Platelet Rich Fibrin (L-PRF, Intra-spin®); improve post-surgical wound healing due to the release of platelet growth factors, promoting angiogenesis and bone and mucosal healing<sup>3</sup>. The properties of autologous platelet concentrates appear particularly useful in BRONJ surgical therapy, as the lack of vascularization represents one of the major factors on pathogenesis of BRONJ. The aim of this study was to evaluate efficacy and safety of L-PRF in conservative surgical approaches of ONJ in osteometabolic patients.

**METHODS:** Two osteometabolic patients, already treated with drugs related to ONJ, were referred to our Sector of Oral Medicine (UNIPA) for bone exposure of the jaw and severe pain. Applying the PROMaF protocol, pre- and post-operative antibiotic systemic treatment was given (ampicillin/sulbactam im and metronidazole per os) as well as the use of chlorexidine mouthwashes and sodium-hyaluronate gel topically. The surgical protocol expected: 1) anesthesia without adrenaline; 2) full-thickness mucoperiosteal flap (when needed); 3) curettage of the necrotic bone, by mean of a piezo-surgery device; 4) irrigation with rifamycin sodium; 5) L-PRF application; 6) tension-free suture. Post-operative instructions were given. Follow-up visits were scheduled 10 days after to remove the suture, then at 1,3 months.

**RESULTS:** Two osteometabolic patients, 64 and 59 years old respectively, were referred to our sector for necrotic bone exposure. The mean cumulative dose of BPs therapy was 15075± 4425mg. Intraoral examinations showed a mucosal fistula that probe to bone in the left side of the mandible in both patients, associated with swelling, lip paresthesia and pain. Both lesions were classified as Stage III, following SICMF-SIPMO clinical and radiological staging system of ONJ. Ten days after the surgery, the wound showed a central depression covered by granulation tissues; nevertheless, the complete mucosal healing was achieved before the next control. Recently, at the last follow-up visit, there were no clinical signs related to ONJ.

**CONCLUSIONS:** Successful treatment is defined as clinical and radiological improvement or as no clinical and radiological signs of ONJ relapse. The combination of gentle surgery and L-PRF application in osteometabolic patients could

offer a practical protocol for bone sequestrectomy in patients receiving oral BPs, avoiding more complex procedures for the clinicians and demanding surgery for the patients. Although with the great limitation of this first report, this preliminary result suggest that L-PRF can act as local regulators of wound healing, accelerating mucosal healing and reducing the surgical time during bone sequestrectomy.

#### REFERENCES:

1. Campisi G *et al.*. Epidemiology, clinical manifestations, risk reduction and treatment strategies of jaw osteonecrosis in cancer patients exposed to antiresorptive agents. *Future Oncol.* 2014 Feb;10(2):257-75.
2. Ruggiero SL *et al.*. American Association of Oral and Maxillofacial Surgeons. American Association of Oral and Maxillofacial Surgeons position paper on medication-related osteonecrosis of the jaw--2014 update. *J Oral Maxillofac Surg.* 2014 Oct;72(10):1938-56.
3. Del Fabbro M *et al.*. Autologous platelet concentrates for bisphosphonate-related osteonecrosis of the jaw treatment and prevention. A systematic review of the literature. *Eur J Cancer.* 2015 Jan;51(1):62-74.

### **B16 - Osteonecrosis of jaw after sunitinib and denosumab: when bone scan is more sensible than computed tomography: a case report**

M. Migliario\*, L. Tommasi, L. Benzi, C. Mortellaro, V. Fusco  
*Dental Unit, AOU Maggiore della Carità, and Dept Health Sciences - Università del Piemonte Orientale, Novara (Italy). Oncology Unit, Nuclear Medicine Unit, Radiology Dept. and "Centro Documentazione Osteonecrosi", Azienda Ospedaliera "SS. Antonio e Biagio e C. Arrigo" - Alessandria (Italy)*

**BACKGROUND:** ONJ after bisphosphonates (BP) treatment was firstly recognized in 2003, and it was largely described as BRONJ (BP-related ONJ). Definition and staging of BRONJ are controversial; the AAOMS definition (2007 – 2009 – 2014) appear too much restricted, based only on clinical features (bone exposure, lasting more than six weeks), not assuming the importance of bone study with imaging tools. Alternative definitions and staging systems have been published (ie, that one of SIPMO-SICMF), including imaging evaluation, essentially Computed Tomography (CT) scan. After 2009, ONJ cases have been observed after denosumab (an antiresorptive drug different from BP) and after antiangiogenic drugs (even without association of BPs or denosumab). A recent issue is: do those ONJ cases have the same characteristics of BRONJ? Both as clinical behavior and at imaging exams? Some scarce literature data are suggesting of somewhat differences.

**CASE REPORTS:** A 58-year male received treatment including sunitinib and denosumab for metastatic renal cell cancer between 2014 and 2016. On December 2016 he presented one little palatal break (2 mm large) with pus discharge (at level of 2.6-2.7 area), diffuse periodontal disease, teeth mobility. While waiting to undergo a Computed Tomography (CT scan), he had a toothbrush mucosal trauma in the right mandible region, provoking a large (25 mm large, 12 mm high) mucosal break, treated with laser therapy. The CT scan revealed mainly left maxillary sinus inflammation, without evidence of other clear signs of ONJ (slightly higher density of right mandible at 4.4-4.8) Vice versa, a bone scan (Tc-99m scintigraphy) revealed a limited uptake on left maxillary bone (extended upward) and a diffused uptake on mandible bone (chin, and proximal medial areas, a little more extended on right hemi-mandible than on left

one). One month later, the patient showed enlargement of the known little palatal bone exposure and a huge right mandible exposure (region 4.3-4.5), at the level of toothbrush trauma, associated with 4.5 bicuspid mobility (grade 2); he suffered for lip hypoesthesia and not severe pain (VAS 2-3). Unfortunately, follow-up is lacking due to death of the patient, five months later, after cancer progression.

**DISCUSSION:** This case apparently confirms that suni-tinib-related and denosumab-related ONJ might have less pronounced CT alterations in comparison with those usually observed in BRONJ cases. However a possible aid to diagnosis from nuclear medicine techniques is deducible in this case, as well as recently described in BRONJ literature, reporting that bone scan might be more sensible (even if not specific) in identifying ONJ areas.

**REFERENCES:**

1. Bedogni A, Fusco V, Agrillo A, Campisi G. Learning from experience. Proposal of a refined definition and staging system for bisphosphonate-related osteonecrosis of the jaw (BRONJ). *Oral Dis.* 2012;18(6):621-3.
2. Fusco V, Muni A, Rouhanifar H, Greco B, Tommasi L. Is bone scan (Tc99 scintigraphy) uptake predictive of clinical onset of osteonecrosis of jaw (ONJ)? *Ann Stomatol (Roma)* 2014 Apr-Jun; 5(2 Suppl): 11. Published online 2014 May 9. PMID: PMC4377671
3. Thomas C, Spanidis M, Engel C, *et al.* Bone scintigraphy predicts bisphosphonate-induced osteonecrosis of the jaw (BRONJ) in patients with metastatic castration-resistant prostate cancer (mCRPC). *Clin Oral Investig.* 2016 May;20(4):753-8. doi: 10.1007/s00784-015-1563-8. Epub 2015 Aug 26.

**B17 - L-PRF AND LLLT as adjuvant treatments in MRONJ: case series**

A. Montori\*, F. Rocchetti, A. Del Vecchio, G. Palaia, G. Tenore, D. Gaglioti, U. Romeo

*DAI Head-Neck, Policlinic Umberto I, Rome, Italy*

**BACKGROUND:** Nowadays MRONJ's management remains a challenge. The choice between conservative and invasive treatments must be established case-by-case. Complementary treatments include the use of low level laser therapy (LLLT) and platelets concentrates with the aim to improve bone and mucosal healing. Among platelet concentrates, leukocyte and platelet-rich fibrin (L-PRF) is the most recently introduced. L-PRF consists in an autologous three-dimensional material with high concentration of leukocytes and growth factors which promotes neo-angiogenesis, inflammatory homeostasis and stimulates collagen production. A specific and validated protocol for using platelet derivatives in dentistry has still not defined; nevertheless, Literature reports countless examples of their application for preventive and therapeutic purposes about the bone and mucosal tissues defects. Specifically, PRF membranes due to the high density of fibrin fibers are very resistant to mechanical stress frequent in the oral cavity and can resist longer to proteolytic degeneration. LLLT is a non invasive treatment with antibacterial, analgesic and biostimulating effects that increases the mitotic index and the differentiation of osteoblasts and relieve pain. The aim of this report is to describe the management of 3 MRONJs patients treated through the L-PRF and LLLT to support the surgical approach.

**METHODS:** Three patients affected by symptomatic MRONJ stage 2 according to SICMF-SIPMO classification were treated at our Department. One lesion appeared on the toothless ridge bone of the third quadrant in a patient treated with Zometa®; the

other 2 cases were caused by implant rehabilitation respectively of tooth 4.6 in a patient treated with Xgeva® and of tooth 2.4 in a patient who had assumed Zometa®. All patients followed their treatments along 2 years.

All the patients received the same protocol:

— Pre-surgical: 1g of Amoxicillin + Clavulanic Acid and 500 mg of Metronidazole route os twice a day starting three days before surgery and with mouth rinses with 0,2% chlorhexidine gluconate.

— Surgical: necrotic bone was removed with piezosurgery and rotary burs, a curettage was performed until bleeding. L-PRF membranes were obtained through a single centrifugation of patient's blood samples for a period of 12 minutes at 400 rpm, using the L-PRF centrifuge IntraLock® International. After centrifugation, each L-PRF clot was separated from serum and placed on a sterile surgical plate in order to obtain two thin membranes that were accurately positioned on the bone defects and stabilized with a resorbable suture.

— Post-surgical: for 7 days after surgery the same antibiotic and antiseptic regimen of preoperative was prescribed and patients received daily applications of LLLT with a double diode laser (Lumix 2 Prodent, Italy), realizing scanning movement on the surgical site with 0,5 W in CW for 15' at 146,7 J. Patients were followed up to 3 months postoperatively.

**RESULTS:** Complete healing of the MRONJ sites were observed for 2 patients while the third one had recurrence.

**CONCLUSIONS:** Despite our limited experience, L-PRF and LLLT may contribute to a successful outcome in MRONJ management. L-PRF acts as a physical barrier against microorganisms while LLLT stimulates tissue regeneration and angiogenesis, accelerating the healing process. Further studies on a larger group of patients with a longer follow-up are needed to confirm the efficacy of the association of L-PRF and LLLT.

**REFERENCES:**

1. Lopez-Jornet P, Sanchez Perez A, Amaral Mendes R, Tobias A. Medication-related osteonecrosis of the jaw: Is autologous platelet concentrate application effective for prevention and treatment? A systematic review. *Journal of Cranio-Maxillo-Facial Surgery* 44 (2016) 1067-1062.
2. Correa Momesso GA, De Souza Batista FR, Alves de Sousa C, Nunes de Lima V, Braga Polo TO, Suerni Hassumi J, Rangel Garcia Junior I and Perez Faverani L. Successful use of Low-Level Laser Therapy in the Treatment of Medication-Related Osteonecrosis of the Jaw. *J Laser Med Sci.* 2017 Autumn; 8(4): 201-203.
3. Raeissadat SA1,1, Babae M1,1, Rayegani SM1,1, Hashemi Z1,1, Hamidieh AA2,2, Mojgani P3,3, Fouladi Vanda H4,4. An overview of platelet products (PRP, PRGF, PRF, etc.) in the Iranian studies. *Future Sci OA.* 2017 Jul 28;3(4):FSO231. doi: 10.4155/foa-2017-0045. eCollection 2017 Nov.

**B18 - CGF membrane in the management of medication related osteonecrosis of the jaw: a case report**

L. Sardelli, R. Ippolito, R. Parrulli, F. Bolognesi, C. Marchetti  
*Unit of Oral and Maxillofacial Surgery, Department of Biomedical and Neuromotor Science (DIBINEM), Alma Mater Studiorum, University of Bologna, Bologna, Italy*

Medication-related osteonecrosis of the jaw (MRONJ) is a severe complication of certain drugs used for the treatment of osteo-metabolic or cancer disease. To date, the management of this complication is controversial and variable on the basis of the necrosis

staging. (1) Indeed, in some cases of established osteonecrosis a conservative approach - which usually consists of antimicrobial therapies, oral antimicrobial rinses, and minimal debridement - is not sufficient to control the over-infection of the necrotic bone, and it is also unable to manage the related symptoms. In those cases surgery is the only strategy that allows us to eliminate the symptoms and eventually to resolve the complication. The main goal of the surgical procedure is to remove the osteonecrotic bone while pursuing a primary intention healing of the soft tissue. The latter is not always achievable due to the poor quality of the surrounding tissue. As we can find in literature, concentrated growth factor (CGF) with a high concentration of platelets in a small volume of plasma, containing also growth factors, leukocytes and fibrin matrix, represents an easily usable product in regenerative medicine. The high concentration of growth factor (PDGF, VEGF, TGF $\beta$ , EGF, etc.) and fibrin fibers derived by autogenous blood centrifugation has the potential to become one of the solutions at hand when improving tissue healing which can potentially be used for MRONJ surgical management. (2) Various studies divided platelets-derived products in different families on the basis of endogenous fibrin and cell content. These characteristics are able to influence the dissolving time of CGF and consequently the rate of growth factors release. (3) In this case report we want to share our findings concerning two patients affected by bisphosphonate-related osteonecrosis of the jaw. They both presented exposed bone areas that were treated with curettage of the osteonecrotic bone and application of CGF membrane obtained from autogenous blood centrifugation. Despite the failure of the primary intention healing, the exposed CGF membrane was still exposed *in situ* after one week, and the tissue healed after the second intention healing fulfillment. Follow up after three months revealed absence of symptoms and signs and no bone exposition or fistulae, which suggests the resolution of the acute severe infection.

#### REFERENCES:

1. Ruggiero SL, Dodson TB, Fantasia J, Goodday R, Aghaloo T, Mehrotra B, O’Ryan F; American Association of Oral and Maxillofacial Surgeons. American Association of Oral and Maxillofacial Surgeons position paper on medication-related osteonecrosis of the jaw--2014 update. (2014) *J Oral Maxillofac Surg*;72(10):1938-56.
2. Inchingolo F, Cantore S, Dipalma G, Georgakopoulos I, Almasri M, Gheno E, Motta A, Marrelli M, Farronato D, Ballini A, Marzullo A. Platelet rich fibrin in the management of medication-related osteonecrosis of the jaw: a clinical and histopathological evaluation. (2017) *J Biol Regul Homeost Agents*. 31(3):811-816
3. Dohan Ehrenfest DM, Bielecki T, Jimbo R, Barbé G, Del Corso M, Inchingolo F, Sammartino G. Do the fibrin architecture and leukocyte content influence the growth factor release of platelet concentrates? An evidence-based answer comparing a pure platelet-rich plasma (P-PRP) gel and a leukocyte- and platelet-rich fibrin (L-PRF). (2012) *Curr Pharm Biotechnol*.13(7):1145-52.

### **B19 - Mandible osteonecrosis in patient in therapy with bisphosphonates**

C. Mirelli, A. Bellina, S. Pieriboni\*, N.A. Dini, L. Bartorelli  
*Fondazione IRCCS Cà Granda Ospedale Maggiore Policlinico, Dental and Stomatology Clinic of the University of Milan, Department of Conservative and Endodontics, Milan, Italy*

**BACKGROUND:** In 2005, “PROGETTO BIFOSFONATI” was born at the Dental Clinic, Department of Conservative

and Endodontics, directed by Professor Bartorelli. This project, born only for the BRONJ problem, then evolved taking interest in drug related Onj (DRONJ). Patients are sent either by different departments of the Dental Clinic or by freelance dentists outside the hospital, or by the Milan Polyclinic departments such as Oncology, Hematology, Bone Metabolism. The aim of this project is to create a reference service, operating in the territory, for prevention, treatment and monitoring patients with or at risk of ONJ.

**PURPOSE OF THE WORK:** We report an emblematic case of mandible osteonecrosis in a patient suffering from multiple myeloma demonstrating the sequence of useful interventions resolving, in a short time, the situation of serious discomfort. **METHODS:** Patient P.E.C., lady of 78, was sent to our observation by the Policlinic Department of Hematology, for pain and mobility of the dental elements, from 33 to 44. The patient was suffering from multiple myeloma Ig Lambda, IIA stage, diagnosed on 2010. She was subjected to chemotherapy protocol, and to zoledronic acid monthly from 2010 to 2013 and then once a year up to 9 months before arriving in our department.

**CLINICAL CASE:** The oral examination confirmed the mobility of the aforementioned dental elements and the bone exposure in chin region vestibularly. The OPT and the TC were examined, both highlighting radiolucency and bone sequestration from 3.4 to 4.3. We proceeded by explaining the situation and contacting the Maxillofacial Surgery department for a first urgent visit. After three weeks, under general anesthesia and antibiotic therapy, a curettage was performed of symphyseal mandibular osteonecrosis in the 33-43 region with contextual avulsion of the dental elements included in the necrotic area: 31, 32, 33, 41, 42, 43 and 44. The surgical piece was sent to the laboratory for histological examination: it result to be bone tissue with marked trabecular re-adaptation and necrosis. After 10 days the surgical wound healing appeared to be excellent, but patient oral mucosa showed a slight exposure of the cortical bone at 34 area. For this reason she was sent to the oral surgery department of the Dental Clinic for extractions of all the remaining teeth of the jaw that was performed under broad-spectrum and full-dose antibiotic therapy for a duration of 10 days starting 2 days before surgery. In the post operative period, the patient applied topically a chlorhexidine gel, ice, used a semi-solid diet and was inserted into a monthly hygiene program. Once healing was happened, prosthetic rehabilitation has been scheduled, to be carried out at the Prosthetic Department of the Odontological Clinic.

**CONCLUSIONS:** The participants of the “Progetto Bifosfonati”, during the course of the anamnestic collection and the first visit, identified the induced osteonecrotic drug problem; this identification allowed to optimize the diagnostic and therapeutic assistance path, ensuring a high quality of the services provided. Especially in this case it is clear how the collaboration of the different departments involved is valid in the management of the emergency; this protocol also applies to patients at risk or who have already taken their therapeutic path. The intervention protocol resulting from our experience from 2005 to today allowed us to reduce waiting times offering a specialized reference point.

#### REFERENCES:

1. Dall’Agnola C., Grimaldi R., Mantovani S., Mirelli C., Scandola O., Teti P., Aspesi M., Rocco B., Santoro G.: “Osteonecrosi dei mascellari e bifosfonati: protocollo d’informazione, prevenzione ed assistenza al paziente nell’esperienza di reparto”, *Doctor Os*, Settembre 2008; 19(7); 779-782.

2. Scarpellini, F. Federghini, M. Rondena *et al.* (2008) Linee guida per la prevenzione, la diagnosi e la cura dell'osteoporosi. Azienda Sanitaria Locale della provincia di Milano n°1 Dipartimento cure primarie U.O.C. assistenza specialistica
3. American Association of Oral and Maxillofacial Surgeons. Position Paper on Bisphosphonate-Related Osteonecrosis of the Jaws. *J Oral Maxillofac Surg* 2007; 65:369-376

## ESPERIENZE PREVENZIONE

### C01 - Prevention, management and follow-up of MRONJs in the cancer-network era

A. Guida <sup>1</sup>\*, S. D'Auria <sup>2</sup>, S. Villano <sup>2</sup>, M. G. Maglione <sup>1</sup>, F. Ionna <sup>1</sup>

<sup>1</sup>S.C. *Chirurgia Maxillo-Facciale-ORL, INT – IRCCS “Fondazione G. Pascale”, Naples, Italy;* <sup>2</sup>S.C. *Direzione Medica di Presidio, INT – IRCCS “Fondazione G. Pascale”, Naples, Italy*

**BACKGROUND:** The number of cancer diagnoses is rapidly growing due to improved treatment and ageing population. Increasing number of treatments/provisions is a major issue for Italian Health Systems and, as timeliness is crucial when curing cancer, keeping waiting lists short is the main goal. In order to improve efficiency, Regions have been organizing, from 2017, Cancer Networks (Rete Oncologica, RO), led by a dedicated Oncologist in a first level center, in order to maximize the effectiveness of Diagnostic-Therapeutic-Pathways (Percorsi Diagnostico – Terapeutici Assistenziali, PDTA). First level center is the venue of the multidisciplinary team (Gruppo Oncologico Multidisciplinare, GOM)- in which different medical specialists work together to plan the therapeutic pathway – and, when needed, is where major surgery is performed. Second level centers are identified by GOMs, in order to refer patients for chemotherapy (CT), radiotherapy (RT) and minor surgery, following GOM's instructions. Qualified medical specialists/general practitioners spread on the territory will act as third level, following-up patients. As desirable, the numbers of patients undergoing CTs will exponentially grow up. Medicament Related Osteonecrosis of the Jaws (MRONJ) is a major issue for CT patients and oncologists need to be supported constantly by the dentist in order to perform prevention, early diagnosis and therapy of MRONJ. We will now report the earliest experience of INT – IRCCS “Fondazione G. Pascale” of Naples, Italy, first level center of RO Campania, in the management of MRONJ throughout the different levels of RO.

**METHODS:** From February 2018, an Oral Pathology Practice (OPP) with a dedicated dentist (specialist in Oral Surgery) has been implemented. All physicians involved in the prescriptions of drugs known as a potential cause of MRONJ and in the follow-up of those patients will be instructed, both with update courses and pamphlets, in referring to the OPP all patients who are undergoing/have undergone/are about to begin CT, for complete dental evaluation. Patients' anamnesis, CT and MRONJ details will be registered, for retrospective evaluation.

**RESULTS:** Remediation of dental foci will be performed prior to start CT; full mouth-hygiene instruction will be given to patients in order to reduce MRONJ risk. OPP will take charge of the patients, organizing their dental therapies and follow up, in accordance with the prescriber, deciding when suspending CT in order to perform dental surgery or MRONJ therapy (antibiotics, minor and major surgery). When non-

surgical dental therapies are needed, patients will be referred to their own dentist.

**CONCLUSIONS:** MRONJ may be a major issue for patients undergoing CT. With the birth of ROs, the numbers of CTs will dramatically grow up, and these patients will find themselves being treated/ followed-up in centers where there may be no dentist nor other dedicated specialist to manage prevention, early diagnosis and therapy of MRONJ. Both patients and prescriber physicians need to be supported in order to minimize such complications. Through accurate registration of patients' anamnesis, CT and MRONJ details, retrospective analysis will be performed, to evaluate criticisms and success of this model of work, also investigating incidence and therapeutic approaches of MRONJ.

#### REFERENCES:

1. Ruggiero SL *et al.* American Association of Oral and Maxillofacial Surgeons. American Association of Oral and Maxillofacial Surgeons position paper on medication-related osteonecrosis of the jaw--2014 update. *J Oral Maxillofac Surg.* 2014 Oct;72(10):1938-56.
2. Muthukrishnan A *et al.* MRONJ risk reduction pathway - 360 degree survey. *Br Dent J.* 2017 Mar 10;222(5):386-390.
3. Rogers SN *et al.* United Kingdom nationwide study of avascular necrosis of the jaws including bisphosphonate-related necrosis. *Br J Oral Maxillofac Surg.* 2015 Feb;53(2):176-82.

### C02 - prevention in medication-related osteonecrosis of the jaw: a review

S. D'Agostino\*, S. Maida, K. Besharat, M. Dolci

*Università degli Studi G. d'Annunzio, Chieti, Pescara, Italy*

The treatment of osteoporosis and cancer bone lesions can involve drugs interacting with bone metabolism (bisphosphonate, antiangiogenic agents, denosumab) which may lead to osteonecrosis of the jaw (MRONJ) as side-effect. This necrosis was firstly related to bisphosphonates therapy in 2003, and then renamed in 2014 by Ruggiero *et al.* due to the growing number of cases connected with other non-bisphosphonate medicines. The purpose of this review is to establish if there is a common scheme in literature for preventing this condition that has a variable frequency but, if not treated, cause always negative impact on the quality of life above all in patients with severe concomitant diseases. A digital search was performed using MEDLINE (PubMed), Cochrane library and World Health Organization International Clinical Trials Registry Platform (WHO ICTRP), by choosing a period of the last 5 years and analyzing only free abstracts. The following keywords were used: MRONJ, osteonecrosis, prevention, prophylaxis, review. Fourteen abstracts were considered, but the WHO ICTRP research has led no results due to partially or absent published data in the range of time given. The analysis shows that a program based on three-monthly visits combined with antibiotics prophylaxis before dental extractions, antiseptic mouthwash (e.g. chlorhexidine) and wound closing techniques for avoiding bone contamination and exposure may reduce the risk of MRONJ in advanced cancer patients receiving zoledronic acid. There is no sufficient evidence to support or deny other procedures suggested for MRONJ prevention such as autologous platelet concentrate (APC) put into the postextraction alveolus or hyperbaric oxygen (HBO) in addition to antiseptic rinses, antibiotics and surgery. The same can be said for wound closure by primary or second intention after dental extractions in people treated with oral

bisphosphonates without MRONJ. Further studies are needed to define the most satisfying clinical management of this disease. Prevent MRONJ is an important task, especially in oncological patients, because it implies to lower its symptoms e.g. dysphagia and oral pain and to improve quality of life. It is helpful to this end make dentists aware of their role by identifying patients at risk and submit them to a customized program built on regular visits every three months and if necessary by adding other adjustments with a view to a surgery, like antibiotic prophylaxis before dental extraction and an appropriate wound closure in association with antiseptic rinses.

#### REFERENCES:

1. Interventions for managing medication-related osteonecrosis of the jaw. N. H. Beth-Tasdogan, B. Mayer, H. Hussein, O. Zolk. Cochrane Oral Health Group, 2017.
2. Medication-related osteonecrosis of the jaw: Is autologous platelet concentrate application effective for prevention and treatment? A systematic review. P. Lopez-Jornet, A. Sanchez Perez, R. Amaral Mendes, A. Tobias. Journal of Craniomaxillofacial Surgery, 2016.

### **C03 - The importance of preventive dental procedure strategies reducing the risk of BRONJ in cancer patients with bone metastases: a single center experience**

R. Bonacina\*, S. Arrigoni, V. Martini, R. Curreri, U. Mariani

*Department of Dentistry, ASST-PG23: Ospedale Papa Giovanni XXIII, Bergamo, Italy*

**BACKGROUND:** Bisphosphonate-related Osteonecrosis of the Jaws (BRONJ) is known as a possible complication in patients undergoing Bisphosphonate (BP) therapy 1. This disease mostly appears in patients who receive BP therapy to manage metastatic diffusion related to onco-haematological disease 2.

**METHODS:** In our research we included 823 cancer patients (median age 67 years, 472 female, 351 male) candidate to BP therapy and referred to our unit since January 2007 to December 2017. All of them accepted a preventive dental protocol before BP therapy. None patient had received head and neck radiotherapy. We divided our patient pool in two different groups. Group1 included 560 cancer patients (340 female, 220 male) who suffer of different cancer types: 266 breast cancer, 128 prostatic adenocarcinoma, 72 lung carcinoma, 28 renal cell carcinoma, 66 patients with primary cancer in other body sites. Group2 included 263 haematological patients (132 female, 131 male); all suffering of multiple myeloma. Preventive dental procedures had the goal to reduce bacterial disease in oral cavity: apart common dental hygiene procedures, we removed infected teeth, and roots, and dental implants with severe perimplantitis. All patients received Zoledronic Acid (ZA) infusions. All the surgical procedures were performed before beginning of therapy and the ZA therapy started only after a complete healing. During and after BP infusions all patients came to our department for 6 months follow up visits and they were referred to their dentist if hygiene or conservative dental procedures were needed. The total number of ZA infusions was 9276; the average for each patient was 11.27 ( 11.45 in G1, 10.82 in G2). The mean days of our follow up was 824.07 days (732.72 for G1 patients, 1018.62 for G2 patients).

**RESULTS:** In our pool 11 cases of BRONJ were detected: 7

patients from cancer group (G1), 4 from multiple myeloma group (G2). BRONJ prevalence was 1.34% in our patients (1.52% in G2, 1.25% in G1). The mean number of ZA infusions at BRONJ diagnosis time was 11.94 (13.83 cycles for G2 and 10.9 cycles for G1). The detectable trigger event of BRONJ was unknown for 4 patients (3 from G1, 1 from G2); the most frequent precipitating factor was the need of surgical dental procedures during ZA therapy: 7 BRONJ cases (4 cases in G1, 3 cases in G2).

**CONCLUSIONS:** The low BRONJ rate after pre-therapy procedures shows the importance of a correct preventive dental protocol and of an adequate long term follow up scheme.

#### REFERENCES:

1. American Association of Oral and Maxillofacial Surgeons position paper on medication-related osteonecrosis of the jaw--2014 update. J Oral Maxillofac Surg. Oct;72(1):1938-56, 2014.
2. Marx R, Sawatari Y, Fortin M, Broumand V: Bisphosphonate induced exposed bone (osteonecrosis/osteopetrosis) of the jaws: risk factors, recognition, prevention and treatment. J Oral Maxillofac Surg, 63:1567, 2005.
3. Vescovi P, Nammour S: Bisphosphonate-related osteonecrosis of the jaws (BRONJ) therapy: a critical review. Min Stomatol, Apr 59(4):181-213, 2010.

### **C04 - Periodontal indices evaluation in presence or absence of osteonecrosis of the jaw in patients on antiresorptive therapy**

J. Forgiione\*, A. Giraud, E. Lerda, A. Gambino, M. Carossa, P. G. Arduino, S. Carossa

*Department of Surgical Sciences, CIR Dental School, University of Turin, Turin, Italy*

**BACKGROUND:** Bisphosphonates are a class of drugs used in cancer patients affected by breast cancer, prostate cancer and multiple myeloma, and in osteometabolic diseases (osteoporosis, Paget's disease and osteogenesis imperfecta). Their function is to inhibit bone resorption mediated by osteoclasts, causing apoptosis of the latter. Their main complication is osteonecrosis of the jaw (ONJ), which is defined as a bone exposure of the maxillofacial region that does not spontaneously regress within 6-8 weeks by its identification, in absence of radiation therapy of the cervicofacial district, in patients under bisphosphonates therapy. The development of this pathology is based on an interaction between different systemic and local risk factors, and furthermore the dento-periodontal diseases.

In order to counteract this disabling adverse effect, targeted prevention must be implemented in populations exposed to ONJ risk.

**AIM:** The objective of this study is to assess whether there is a statistically significant correlation between the various periodontal indices and the onset of ONJ in patients undergoing bisphosphonates therapy.

**METHODS:** The dento-periodontal indices of a group of patients treated with bisphosphonates belonging to the Oral Surgery Department of the Dental School of the University of Turin were evaluated before the beginning of the therapy from July 2016 to February 2018. These patients were divided into 2 groups: those who developed osteonecrosis (ONJ+) and patients who did not develop osteonecrosis (ONJ-) during the observation period. For each index, its correlation has been calculated with the development of osteonecrosis of the jaw. The parameters evaluated are gender, age, full mouth plaque score (FMPS), full mouth bleeding score (FMBS), periodon-

tal screening recording (PSR), and presence or absence of prostheses.

**RESULTS:** Data on 108 patients have been collected: 53 of the ONJ- group and 55 of the ONJ + group. A statistically significant difference in FMPS was found between the two groups: in ONJ + patients the plaque index average is 52.77% against 35.15% of patients in the ONJ - group. Furthermore, a statistically significant correlation between onset of osteonecrosis and patient seniority was detected, with a mean age of the ONJ- and ONJ+ of 64.81 and 72.42 years, respectively. On the other hand, FMBS revealed a milder involvement in the ONJ + group (14.55%) than in ONJ- group (17.49%)

**CONCLUSIONS:** A poor oral hygiene pattern might predispose the patients under antiresorptive agents to a higher probability of developing osteonecrosis of the jaw. Older patients receiving bisphosphonate therapy seem to be more likely to contract ONJ. In the light of these results, a primary prevention program is needed, in order to improve and screen the oral hygiene of these patients, enlightening them on the relationship between a greater amount of plaque and the possible onset of ONJ; moreover, older patients should undergo more frequent professional oral hygiene checks and recalls, thus intercepting the arising of early injuries.

**REFERENCES:**

1. Aliya A Khan, Archie Morrison, David A Hanley; Diagnosis and Management of Osteonecrosis of the Jaw: a Systematic Review and International Consensus (2015)
2. L. Ruggiero, SB. Woo Bisphosphonate-related osteonecrosis of the jaws. *DentClin N Am* 52 (2008)
3. Hansen T, Kunkel M, Weber A, James KC. Osteonecrosis of the jaws in patients treated with bisphosphonates – histomorphologic analysis in comparison with infected osteoradionecrosis (*J Oral Pathol Med.*(2006;35:155–60)

### **C05 - The role of dental hygienist in the prevention of medication-related osteonecrosis of the jaws (MRONJ): a therapeutic approach**

M. Logiudice\*, A. Gambino, P. Carcieri, F. Erovigni, P.G. Arduino

*Department of Surgical Sciences, Oral Medicine Section, CIR Dental School, University of Turin, Turin, Italy*

The aim of this research is to define a professional oral hygiene protocol to be applied not only in patients affected by MRONJ, but also in patients with an underlying risk of developing MRONJ. These patients require a thorough management, based on preventive care, early detection and non-surgical treatment with continuous monitoring and maintenance, in order to minimize the risk of developing MRONJ. The exact underlying etiopathogenic mechanism of MRONJ is still unclear, with dental extraction and severe periodontal disease as the only factors significantly associated with its occurrence. The relationship between preventive treatment protocols and improvement of oral hygiene with a lower rate of MRONJ has been usually investigated, retrospectively: in 2013, Krimmel evaluated the time of occurrence of ONJ after treatment onset with bisphosphonates using Kaplan–Meier estimator and logrank test (level of significance 0.05). This study highlighted the great benefit of good dental and oral health in the prevention of MRONJ: in fact, without parodontal treatment, MRONJ occurred 15 months earlier compared to patients undergoing parodontal treatment ( $p=0.12$ ). Measures to effective prevention are: 1) conventional oral examination (COE), 2) minimally invasive procedures, 3) maintenance of

appropriate oral hygiene, 4) continuous monitoring during and after therapy. COE allows us to identify all local and systemic risk factors, provide information on ONJ, acquire radiographic and photographic images. The professional oral hygiene protocol of this proposal includes the periodontal chart and minimally invasive procedures, following criteria proposed by Ribeiro in 2011. During maintenance therapy, if tissues are tonic and there are not sites of active periodontal disease, it is possible to apply the method suggested by Flemming in 2012, involving the use of powders for plaque removal. A complete healing of periodontal tissues after causal therapy is mandatory for those who are going to be treated with an antiresorptive and/or antiangiogenic agent; on the other hand, an oral non-traumatic hygiene is always recommended, usually combined with antibiotic prophylaxis, for either patients undergoing previous or current therapy with bisphosphonates or those already affected by MRONJ. Low Level Laser Therapy seems to be a promising adjuvant treatment, due to its abilities to improve the wound healing, relieve pain, as well as providing antibacterial and biostimulating effects on soft and hard tissues. Dental hygienist plays a very important role in finding early mucosal lesions which can lead to bone exposure, especially among patients with no clinical complaint, yet. To date, there are no prospective studies regarding the onset of osteonecrosis after professional oral hygiene sessions. Considering the role of dental hygienist on primary and secondary prevention of oral diseases, this professional figure must be fully involved since the beginning of the therapeutic management of these patients.

**REFERENCES:**

1. Krimmel *et al.* Does dental and oral health influence the development and course of bisphosphonate-related osteonecrosis of the jaws (BRONJ)? *OralMaxillofacSurg* 2014;8(2):213-8.
2. Ribeiro FV *et al.* Clinical and patient-centered outcomes after minimally invasive non-surgical or surgical approaches for the treatment of intrabony defects: a randomized clinical trial. *J Periodontol.* 2011;82(9):1256-66.
3. Flemming TF *et al.* Randomized controlled trial assessing efficacy and safety of glycine powder air polishing in moderate-to-deep periodontal pockets. *J Periodontol.* 2012;83(4):444-52

### **C06 - ONJ in osteometabolic patients: no guilty verdict for teeth extraction**

L. Maniscalco <sup>1\*</sup>, R. Maucri 2, V. Panzarella 2, V.R.M. Muggeo 3, G. Campisi <sup>1,2</sup>

*<sup>1</sup>Dipartimento di Chirurgia Neurosensoriale e Motoria, Medicina Orale con Odontoiatria per Pazienti a Rischio, AOUP "Paolo Giaccone" Palermo, Italy; <sup>2</sup>Dipartimento di Discipline Chirurgiche, Oncologiche e Stomatologiche, Università di Palermo, Palermo, Italy; <sup>3</sup>Dipartimento di Scienze Economiche, Aziendali e Statistiche, Università di Palermo, Palermo, Italy*

**BACKGROUND:** Osteonecrosis of the jaw (ONJ) is an adverse effect of bone-targeted agents in cancer and non-cancer patients<sup>1</sup>. Its pathophysiology has not been fully elucidated, however, the adoption of preventive measures is up to date the best chance to reduce ONJ incidence<sup>2</sup>. The aim of this study is to evaluate retrospectively the impact of some variables on the risk of ONJ onset in osteometabolic non-cancer patients by logistic regression analyses.

**METHODS:** 106 osteometabolic patients under bisphospho-



nate (BP) treatment were consecutively referred to Sector of Oral Medicine (UNIPA) from 2012 to 2016. In particular, 60 osteometabolic patients used alendronate as a BP type was considered for the statistical analysis. The collected variables were: demographic data (i.e. age, gender), concomitant systemic diseases, smoking habits and history of dental extraction. Descriptive statistics were carried out, logistic regression models were applied. Classical logistic regression model led to big standard errors, wide confidence interval, and, consequently, to a wrong interpretation of the coefficients. For this reason, a penalized logistic model with Firth's penalization<sup>3</sup> was appropriately used. P-value was set to <0.05 as significant.

**RESULTS:** The mean age of the 60 patients was 71.25±8.78 years, 93% were female. The mean therapy duration was 77.80±43.05 months with a cumulative dosage of 21780±12054.04 mg. Most of the patients had no history of smoking (78%), 83% of patients reported to undergo at least one dental extraction. Ten percent of patients (n=6) showed ONJ. Sixty-seven percent suffered from at least one concomitant systemic disease. The regression model showed that the binary variable extraction (OR= 0.158) is a protective factor for ONJ, that is for a given osteometabolic patient taking alendronate, who undergoes dental extraction ONJ onset is less probable with respect to a patient (similar for local and systemic diseases) without a history of dental extraction. This result supports the recent literature where dental extraction seems to be incidental to the disease, due to underlying local infective disease, and it is not directly responsible for the ONJ onset<sup>4</sup>. The number of concomitant systemic diseases, gender and therapy duration have been found not to affect the ONJ onset probability.

**CONCLUSIONS:** Our analysis shows that tooth extraction decreases the chance to develop ONJ. Furthermore, it seems that systemic comorbidities, gender and therapy duration do not affect the ONJ onset.

#### REFERENCES:

1. Di Fede O, Fusco V, et al.; Osteonecrosis of the jaw in patients assuming oral bisphosphonate for osteoporosis: A retrospective multi-hospital-based study of 87 Italian cases. *European Journal of Internal Medicine*. 2013 Dec;24(8):784-90.
2. Campisi G, Fedele S, Fusco V, Pizzo G, Di Fede O, Bedogni A. Epidemiology, clinical manifestations, risk reduction and treatment strategies of jaw osteonecrosis in cancer patients exposed to antiresorptive agents. *Future Oncol*. 2014 Feb;10(2):257-75.
3. Firth, David. "Bias reduction of maximum likelihood estimates." *Biometrika* 80.1 (1993): 27-38.
4. Dodson, Thomas B. "The frequency of medication-related osteonecrosis of the jaw and its associated risk factors." *Oral and Maxillofacial Surgery Clinics* 27.4 (2015): 509-516.

### **C07 - b.P.F.C.® Bio-plasma® with pure growth factors (bioPlasma®) for the surgical treatment of patients at risk of maxillary osteonecrosis, related to bisphosphonates (BRONJ)**

R. Viganò<sup>1</sup>, L. Viganò<sup>2</sup>, C. Casu<sup>3</sup>

<sup>1</sup>Freelance, Varese, Italy; <sup>2</sup>University of Milan, Department of Radiology, Milan, Italy; <sup>3</sup>Private Dental Practice, Cagliari, Italy

**BACKGROUND:** The aim of this study was to evaluate the efficacy of a new platelet-rich plasma preparation and its

regenerative capacity of Bone Tissue (GBR) and Soft Tissues (GTR), for the treatment of patients with risk of maxillary osteonecrosis, related to bisphosphonates (BRONJ) using a pure platelet concentrate without the use of anticoagulant, nor any type of activator. For this reason it has been called "Pure" it is the B.P.F.C.® Bio-Plasma® with Pure Growth Factors (BioPlasma®) designed and developed by Dr. Raffaello Viganò (Varese Italy 2010), to promote the healing process in patients with BRONJ.

**METHODS:** 17 patients undergone to oral (4 patients) or injective bisphosphonates (13 patients) at least for 2 years, were enrolled in this study. The patients received the avulsion of root residues. They are treated with a regenerative surgical procedure using a rich BioPlasma® preparation with Pure Growth Factors. All patients have read and signed a written consent form. The study protocol was approved by the Ethics Committee for Human Studies of the "Ospedale di Circolo" - University of Varese, and was conducted in accordance with the 1975 Helsinki Declaration, amended in 2000. The phases of the study were: taking blood from the patient with Vacuette 9 ml; centrifugation and fractionation of the blood material; creation of the membrane with a mixture of fibrin and poor plasma; preparation of rich gelled plasma and placement at the bone site (after avulsion and bone curettage); positioning of the membrane above the rich plasma; final suture with minimal exposure of the membrane.

**RESULTS:** No patient discontinued the use of BPs only because of the need for surgery. No intraoperative or post-operative complications were observed, and all 17 patients were successfully treated, without development of BRONJ. Patients were observed for the next 6 months without showing bone exposure.

**CONCLUSIONS:** Our data showed how the preparation of Bio-Plasma® with Pure Growth Factors, inserted in the the alveolus after avulsion of patients at risk of BRONJ, associated with the use of fibrin enriched with poor Plasma as a suturing membrane cover, is able to provide perfect healing with the integrity of the hard and soft tissue after 6 months. The membrane made with a mixture of fibrin and poor plasma is important for the protection of the surgical site from penetration bacteria. Further studies are needed to validate these results with a larger sample size and longer follow-up time.

### **C08 - Development of OloHealth, a teledentistry platform for the ONJ prevention in Sicily: preliminary reports**

R. Mauceri<sup>1,2</sup>, O. Di Fede<sup>1</sup>, D. Montemaggiore<sup>1</sup>, G. Campisi<sup>1,2</sup>, V. Panzarella<sup>1</sup>

<sup>1</sup>Dept. of Surgical, Oncological and Oral Sciences, University of Palermo, Palermo, Italy; <sup>2</sup>Oral Medicine and Dentistry for patients with special needs, Department of Sensorineural and Motor Surgery, AUOP "P. Giaccone" of Palermo, Palermo, Italy

**BACKGROUND:** The entire process of networking, sharing digital information, distant consultations, workup and analysis is performed and known as Teledentistry (TD)<sup>1</sup>. Many rural geographical areas are not covered from sufficient oral assistance and care, particularly for management of oral diseases in fragile patients such as osteonecrosis of the jaw (ONJ)<sup>2</sup>. The aim of this study is to describe our preliminary experience by means TD platform, named OloHealth, particularly dedicated to prevention and management of ONJ in oncological patients.

**METHODS:** OloHealth was created in 2018, thanks to the PSN project named “Network per la medicina orale nel paziente anziano (oncologico e fragile)”. It is based on a HUB and SPOKE model network. The HUB is our Sector of Oral Medicine (AUOP “P. Giaccone” of Palermo), also Sicilian main center for the prevention and treatment of ONJ. The hub is connected to several SPOKES (oncological units) in Sicily; each one can log in and to use simply the platform, requiring a teleconsultation or a live consultation. In order to carry out the live consultation, the HUB and SPOKE are simultaneously connected to the OloHealth platform, and the patient’s images are reported by an intraoral camera (i.e. Gendex GXC-300). The live consultation ends with a diagnosis or a temporary diagnosis, medical therapy prescription and, planning a visit at the HUB center for demanding case, if necessary.

**RESULTS:** Olohealth is active since January 2018; actually, it connects the HUB with 4 Oncological Units, so dislocated: 2 in the suburbs of Palermo and 2 in different Sicilian western city (i.e. Trapani and Agrigento). In one month, 15 teleconsultations for oncological patients at risks of ONJ have been requested and performed from the HUB. Twelve teleconsultations regarded the management of cancer patients in a “pre-treatment phase”; due to the analysis of the shared clinical images and the x-ray (i.e. orthopantomogram), dental measures needed to eliminate infective outbreaks were indicated by the HUB and they have been performed by the patient’s dentist at their hometown. Three teleconsultations have been made to assess the presence of osteonecrosis of the jaw in patients under treatment with ONJ-related drug; one has made as live consultation. After the first consultations, computed tomography (CT) are requested for each patient to confirm or not the diagnosis and define the ONJ stage. Medical therapy has prescribed as well as the date for the surgical therapy at the HUB center. All the 15 teleconsultations are performed within 48 hours from the request by the SPOKES.

**CONCLUSIONS:** Teledentistry could be comparable to face-to-face for oral screening due to the reliability showed by the intra-oral camera. This study is the first step of an extensive project at the University Hospital of Palermo and several hospitals in the Sicilian region. Especially for cancer patients, ONJ prevention is important as to give to the patients the chance to undergo dental care directly in their hometown, without undergoing long car journeys. Moreover, the consultations are quickly provided within 48 hours from the request, and, concerning the ONJ cases, the waiting times between the diagnosis and the access to the center for the execution of the surgical therapy have been greatly reduced.

**REFERENCES:**

1. Alabdullah JH, Daniel SJ. A Systematic Review on the Validity of Teledentistry. *Telemed J E Health*. 2018 Jan 5.
2. Campisi G, Fedele S, Fusco V, Pizzo G, Di Fede O, Bedogni A. Epidemiology, clinical manifestations, risk reduction and treatment strategies of jaw osteonecrosis in cancer patients exposed to antiresorptive agents. *Future Oncol*. 2014 Feb;10(2):257-75.

**C09 - Is the presence of dental implants a local risk factor for MRONJ?**

D. Pergolini\*, M. Fioravanti, G. Palaia, A. Del Vecchio, G. Tenore, U. Romeo

*“Sapienza” University of Rome Department of Oral and Maxillofacial Sciences UOC, Rome, Italy*

The aim of this work is to examine if dental implants placed into the bone before starting antiangiogenic or

anti-resorptive drugs could represent a local risk factor for the onset of MRONJ. Medication-related osteonecrosis of the jaw (MRONJ) is defined as an area of exposed bone or bone that can be probed through an intraoral or extraoral fistula in the maxillofacial region that does not heal after 8 weeks observation and conventional therapy, in a patient treated currently or previously with antiresorptive or antiangiogenic drugs, without having ever made radiotherapy in the head-neck region or obvious metastatic disease to the jaws. MRONJ could be subsequent to treatment with antiangiogenic or anti-resorptive drugs, such as bisphosphonates and denosumab, used to manage many diseases, such as osteoporosis, Paget’s disease and neoplasms with bone metastases. MRONJ often occurs in sites with active or chronic oral infections. So, patients should be strictly followed-up it, in order to evaluate and eliminate any infectious odontogenic outbreak. Recent studies have focused on another factor to be evaluated to prevent the development of MRONJ: the presence itself of dental implants into the bone. In fact, not only the implant surgical therapy is considered a risk of factor for MRONJ, but also the presence of a previously placed implant, that is subjected to infections such as mucositis and peri-implantitis, that could support and enhance the process of MRONJ. At the Department of Oral and Maxillofacial Sciences of “Sapienza”, University of Rome, some patients showed MRONJ lesions around dental implants, inserted much time before the detection of the lesion. In these cases, severe MRONJ lesions and osteonecrosis were present only around the implant fixture. According to the literature, our clinical experience assumes that the sole presence of osteointegrated dental implant itself should be considered potentially a continuous local risk factor for the future development of MRONJ. More clinical studies and scientific tests are certainly needed to validate this hypothesis. In the meantime, trained clinicians should pay more attention with close follow-up for a correct and preventive management of patients with dental implants, that are going to take bisphosphonates or anti-angiogenic drugs.

**REFERENCES:**

1. American Association of Oral and Maxillofacial Surgeons position paper on medication-related osteonecrosis of the jaw--2014 update and CTX. Schwartz HC.
2. Osteopathology induced by bisphosphonates and dental implants: clinical observations. Jacobsen C1, Metzler P, Rössle M, Obwegeser J, Zemann W, Grätz KW. *Clin Oral Investig*. 2013 Jan
3. Medication-related osteonecrosis of the jaw: risk factors in patients under biphosphonate *versus* patients under antiresorptive-antiangiogenic drugs. Ghidini G, Manfredi M, Giovannacci I, Mergoni G, Sarraj A, Mureddu M, Giunta G, Bonanini M, Meleti M, Vescovi P. *Minerva Stomatol*. 2017 Aug

**C10 - Lack of adherence to periodontal supportive therapy in oncological patients treated with bone targeting agents. Does it play a role in ONJ development?**

G. Oteri\*, A. Marciano\*

*Department of Biomedical and Dental Sciences and Morphofunctional Imaging, University of Messina, Messina, Italy*

**BACKGROUND:** To prevent medication-related osteonecrosis of the jaw (MR-ONJ) induced by infection and or surgical

injury, periodontal questionable teeth are often extracted prophylactically before receiving bone targeting agents (BTAs). Extensive prophylactic teeth extractions can compromise the patients' quality of life especially when they are a removable prosthesis pillar and has an impact on patients' emotional well-being. The decision to extract asymptomatic teeth before BTAs therapy is actually based on the surgeons personal experience. In cancer patients, the adherence to periodontal supportive therapy (SPT), with regular attendance to follow-up visits and no interruption of more than 1 year, could not be always guaranteed, thus periodontally compromised teeth could represent a factor predisposing to the development of MR-ONJ. In order to address informations to evaluate the risk of MR-ONJ, the aim of the study was to retrospectively assess the compliance in periodontal maintenance, survival rate and stability of periodontally involved teeth in cancer patients treated with BTAs and their extraction needs during the follow-up.

**METHODS:** We retrospectively reviewed the medical and dental records of all patients treated with BTAs who later developed MR-ONJ or not, followed in the Department of Oral Surgery of the University of Messina between 2007 and 2017. Patients were included in the study if they had periodontal disease at baseline and at least one tooth with increased mobility combined with clinical attachment loss and relative bone loss which was whether maintained, splinted or extracted. SPT was assessed through the patient clinical diary in the registry of hospital access to the Unit. Patient clinical history and tooth-related factors were assessed retrospectively before (baseline) and after the beginning of BTAs treatment. Changes in periodontal parameters were assessed through follow-up dental rx and compared to baseline. Teeth extractions were recorded as well as MR-ONJ occurrence and location and the relationship between the two was evaluated.

**CONCLUSIONS:** Partially edentulous cancer patients, if affected by generalized periodontitis prior to start BTAs therapy, frequently showed a worsening of oral health parameters during follow-up. Despite the periodontal stability usually observed in closely monitored patients, this effect may be related to the limited adherence of many oncologic patients to SPT, due to the priority given to primary disease treatment, leading to resistant periodontal infection as well as dental extraction needs. To our knowledge, this is the first attempt to highlight a clinically relevant point that is to maintain or not dental elements with increased periodontal probing depth, loss of clinical attachment and mobility prior to BTAs beginning. Since severe periodontitis may increase the risk of MR-ONJ a more strict tooth extraction protocol is suggested in patients with limited oral compliance.

**REFERENCES:**

1. Ruggiero S, Gralow J, Marx RE, *et al.* Practical Guidelines for the Prevention, Diagnosis, and Treatment of Osteonecrosis of the Jaw in Patients With Cancer. *Journal of Oncology Practice.* 2006;2(1):7-14.
2. Lindhe J, Nyman S. The effect of plaque control and surgical pocket elimination on the establishment and maintenance of periodontal health. A longitudinal study of periodontal therapy in cases of advanced disease. *J Clin Periodontol.* 1975;2:67-79.
3. Sonnenschein SK, Betzler C, Rütters MA, Krisam J, Saure D, Kim TS. Long-term stability of splinted anterior mandibular teeth during supportive periodontal therapy. *Acta Odontol Scand.* 2017 Oct;75(7):475-482.

## TRATTAMENTO ONJ

### D01 - Conservative therapy in patients affected by medication related osteonecrosis of the jaw (MRONJ)

F. Zotti, S. Bonetti\*, F. Lonardi, L. Lanaro, M. Albanese

*Section of Dentistry and Maxillo-facial Surgery, Department of Surgical Sciences, Paediatrics and Gynecology, University of Verona, Verona, Italy*

**BACKGROUND:** Medication Related Osteonecrosis of the Jaw (MRONJ) is an adverse reaction to drugs used to treat dysmetabolic osseous diseases and in the cancer-related conditions management. These cancer-related conditions include malignancy related hypercalcemia and skeletal-related events (SREs) with bone metastases in solid tumors. The choice among surgical or medical treatment depends on the stage of the disease, on the patients' health condition, and his/her life expectancy. Several scientific societies and literature propose staging strategies and then the surgical treatment as a gold standard. However, some pathological conditions, such as high cardiovascular risk, short life expectancy and remarkable extension of disease, do not allow to treat MRONJ surgically.

**METHODS:** An observational study has been carried out, the fundamental criterium to be enrolled in was diagnosis of MRONJ and one or more of the following criteria: refused surgery, high cardiovascular risk (ASA $\geq$ 3), short life expectancy, a remarkable extension of the bone lesion and comorbidities. According to these selection criteria, twelve subjects have been enrolled in the study. Five visits have been scheduled during a 12 months follow-up: T0 (baseline, first visit), T1 (1 month); T2 (4 months), T3 (7 months), T4 (12 months). Mucosal oedema, rubor, halitosis, secreting fistula, bone exposition, rhinosinusitis, pain (VAS scale) have been evaluated at every clinical check in order to stage the disease and to evaluate the success of the medical therapy. Radiological examinations have been performed in each patient at T0 in order to further and better characterize and staging the disease according to the present-day guidelines for staging treatment of ONJ. A protocol of conservative therapy has been designed and administered to the sample as follows: dental hygiene every 4 months, chlorhexidine (0,12%) mouthwashes three times a day (first week for every month), antibiotic treatment: amoxicillin + clavulanic acid (875+125mg) and metronidazole (500mg) 3 times per day (first week of every month). When gastrointestinal disease related to the prolonged antibiotic therapy was present, ciprofloxacin (500 mg) two times per day for 5 days has been prescribed.

**RESULTS:** Inflammation indicators showed a considerable improvement: oedema and rubor in T0 were present in all patients (12/12), in T4 they were completely disappeared. The therapy positively influenced the pain symptoms: they were present in all patients at T0 (Avg VAS 3/10) and they were totally absent at T4. Halitosis also showed a significant improvement (83,3% in T0 and 8,3% in T2). Sinusitis MRONJ-associated usually requires a surgical treatment, however, in one of our patients signs and symptoms of sinusitis recovered by medical treatment only. Secreting fistulas were present in 9/12 patients, they decreased progressively during the follow-up. At T4 only 1 intraoral and 1 extraoral (cutaneous) non-secreting fistulas were observed. Bone exposure it was relatively frequent and it was present in 50% of the patients at T0, it slightly reduced and it was still present in 41,6% of the sample at T4. One spontaneous sequestrectomy has been observed.

**CONCLUSIONS:** Patients enrolled are relatively few, further studies should be carried out to confirm our results. This study suggests that conservative treatment may be an effective alternative treatment for MRONJ in patients ineligible for surgery.

- REFERENCES:**
1. Ruggiero, S. L. *et al.* American Association of Oral and Maxillofacial Surgeons Position Paper on Medication-Related Osteonecrosis of the Jaw—2014 Update. *J. Oral Maxillofac. Surg.* 72, 1938–1956 (2014).
  2. Campisi, G. *et al.* Epidemiology, clinical manifestations, risk reduction and treatment strategies of jaw osteonecrosis in cancer patients exposed to antiresorptive agents. *Futur. Oncol.* 10, 257–275 (2014).
  3. Procacci, P. *et al.* Medication-related osteonecrosis of the posterior maxilla: surgical treatment using a combined transnasal endoscopic and intraoral approach, our experience with seven consecutive patients. *Clin. Otolaryngol.* (2017). doi:10.1111/coa.12999

## D02 - Autologous platelet concentrates for treatment and prevention of MRONJ. A systematic review of the literature

M. Del Fabbro <sup>1,2</sup>, F. Goker <sup>1,2</sup>

<sup>1</sup>Department of Biomedical, Surgical and Dental Sciences, Università degli Studi di Milano, Milan, Italy; <sup>2</sup>IRCCS Istituto Ortopedico Galeazzi, Milan, Italy

**BACKGROUND:** Medication related osteonecrosis of the jaw (MRONJ) is a drug-related adverse event consisting of progressive bone destruction in the maxillofacial region of patients under current or previous treatment with an anti-resorptive agent, the most popular being bisphosphonates. Autologous platelet concentrates (APC) demonstrated to enhance bone and soft tissue healing in oral surgery procedures. This systematic review aimed to evaluate if APC may improve treatment and prevention of MRONJ in patients under antiresorptive therapy.

**METHODS:** An electronic search was performed on the following databases: MEDLINE, Scopus, Web of Science and Cochrane. The following search terms were used: “bisphosphonate”, “denosumab”, “antiresorptive agents”, “antiresorptive therapy”, “BRONJ”, “MRONJ”, “osteoporosis”, “osteonecrosis”, “maxilla”, “mandible”, “platelet-rich plasma”, “platelet concentrates”, “platelet growth factors”, “platelet-rich fibrin”, “PRP”, “PRGF”, “PRF”, “Platelet-Derived Growth Factor”, “PDGF”, “CGF”, “oral surgery”, “extraction socket”, “tooth extraction”. The limit “humans” was applied. For being included, studies had to report clinical results of oral surgery procedures in patients under antiresorptive therapy, in which APC agents were used for improving the clinical outcome. Both articles reporting on the treatment of an existing condition of MRONJ and those reporting on the incidence/onset of MRONJ in patients undergoing oral surgery procedures were considered. Restrictions were not placed regarding the language and the year of publication. Both prospective and retrospective studies with at least 5 patients and 3 months follow-up were included. Case studies/reports were not included. The studies had to provide details on the type and dosage of antiresorptive drug taken, and the indication for antiresorptive therapy. Publications not dealing with original clinical cases (e.g. reviews, technical reports, expert opinions) were also excluded. The main variables extracted from each included study were: study design, study setting (university, hospital, private practice), sample size, patients gender and age, proportion of smokers, type, dosage and administration route of antiresorptive

drug taken, reason for antiresorptive treatment, dosage, duration of treatment at surgery, type of APC used, jaw (maxilla or mandible), any outcome variable used to evaluate treatment success, follow-up duration, complications, adverse events, postsurgical onset/recurrence of MRONJ. The MRONJ staging definition proposed by the AAOMS in 2014 was used as a reference.

**RESULTS:** Thirteen studies were included, reporting on 648 patients undergoing oral surgery. The main surgical procedures were tooth extraction, dental implant placement, resection of necrotic tissue. APCs used were platelet-rich plasma, plasma rich in growth factors, platelet-rich fibrin. Post-surgery follow-up ranged from 3 to 94 months. The adjunct of APC in MRONJ treatment significantly reduced osteonecrosis recurrence with respect to control. APC was associated with a lower BRONJ incidence after tooth extraction, though not significant. Heterogeneity was found regarding medication type, clinical indication, triggering factors, study design, follow-up duration, type of APC, outcomes adopted to evaluate treatment success.

**CONCLUSIONS:** Though the results of this review must be cautiously interpreted, due to the low evidence level of the studies included, and the limited sample sizes, they are suggestive of possible benefits of APC when associated with surgical procedures for treatment or prevention of BRONJ. To confirm such indication, prospective comparative studies with a large sample size are urgently needed.

**Key words:** antiresorptive agents; bisphosphonates; MRONJ; oral surgery; platelet concentrates; tooth extraction

- REFERENCES:**
1. Otto S, Schreyer C, Hafner S, *et al.* Bisphosphonate-related osteonecrosis of the jaws - Characteristics, risk factors, clinical features, localization and impact on oncological treatment. *J Cranio-Maxillo-Facial Surg* 2012;40:303-309
  2. Plachokova AS, Nikolidakis D, Mulder J, *et al.* Effect of platelet-rich plasma on bone regeneration in dentistry: A systematic review. *Clin Oral Implants Res* 2008;19:539-45.
  3. Del Fabbro M, Gallesio G, Mozzati M. Autologous platelet concentrates for bisphosphonate-related osteonecrosis of the jaw treatment and prevention. A systematic review of the literature. *Eur J Cancer* 2015;51:62-74.

## D03 - Ozone gas insufflation and infiltration for conservative surgical treatment of osteonecrosis of the jaw: preliminary results at 3 months

R. Mauceri <sup>1\*</sup>, C. Del Gaizo, L. Lo Muzio <sup>2</sup>, G. Campisi <sup>1</sup>, O. Fede <sup>1</sup>

<sup>1</sup>Dept. of Surgical, Oncological and Oral Sciences, University of Palermo, Palermo, Italy; <sup>2</sup>Dept. of Clinical and Experimental Medicine, University of Foggia, Foggia, Italy

**BACKGROUND:** Osteonecrosis of the jaw (ONJ) is a serious adverse reaction of anti-resorptive (AR) and anti-angiogenic (AA) agents; it is a potentially painful and debilitating condition that can considerably affect the quality of life of patients. Treatment of ONJ is still a challenge and, lately, conservative surgical treatments are increasingly performed at all stages of the disease. In the international literature, the use of ozone (O<sub>3</sub>) is an adjuvant support, taking in account its antimicrobial and wound-healing properties. The aim of this study was to evaluate efficacy and safety of ozone insufflation/injection in conservative surgical approaches of ONJ in two cancer patients.

**METHODS:** Two cancer patients, already treated with drugs related to ONJ, were referred to our Sector of Oral Medicine (UNIPA) for bone exposure of the jaw and severe pain.

**RESULTS:** Anamnestically, the 62-year-old partially edentulous male was affected by multiple myeloma and referred 8 cycles of

AR therapy (i.e. zoledronic acid ev); no consumption of tobacco or high consumption of alcohol were reported. The second patient was a 56-year-old partially edentulous woman affected by breast cancer with bone metastasis; she reported a history of 12 cycles of AR therapy (i.e. denosumab ev) associated with 12 cycles of AA therapy (i.e. afinitor os). Intraoral examinations showed a bone exposure on the left side of the mandible in the man, while a mucosal fistulas that probe to bone was observed in the left side of the maxilla of the woman. CT scans were requested for both and they were inserted into medical therapy PROMaF protocol for acute infection control (<http://www.policlinico.pa.it/portal/index.php?option=displaypage&Itemid=264&op=page&SubMenu>). ONJs were classified as Stage I and Stage II (SIPMO-SICMF staging system), respectively. Applying the PROMaF protocol, pre- and post-operative antibiotic systemic treatment was given (ampicillin/sulbactam im and metronidazole per os) as well as the use of chlorhexidine mouthwashes and sodium-hyaluronate gel topically. The surgical protocol expected: 1) anesthesia without adrenaline; 2) full-thickness mucoperiosteal flap; 3) curettage of the necrotic bone, by mean of a piezo-surgery device; 4) insufflation inside bone defect (15 ml dosage) (by pink Venocat cannula 20G x 1.1/4"/1.10 x 32 mm) and injection around mucosal edges (15 ml dosage) (by 26G x 1/2" needle - 0.45x13mm) of oxygen-ozone mixture (15% concentration); 5) tension-free suture. Post-operative instructions were given. Follow-up visits were scheduled 10 days after to remove the suture, then at 1,3 months. Ten days after, the mucosal healing was partially complete in both patients and no painful symptom was referred from the second day after (NAS scale=1 and , respectively). At one month, the complete mucosal healing was completely achieved. After 3 months of follow-up, no patient shows symptoms or signs related to ONJ.

**CONCLUSIONS:** The combined antibiotic/gentle surgery/O3 procedure could offer a secure and practical protocol for conservative surgical treatments in patients affected by ONJ. Although with the great limitation of these two cases report, we suppose that O3 could ameliorate wound healing, accelerating mucosal healing and potentially reducing the risk of post-operative complications.

#### REFERENCES:

1. Campisi G *et al.*. Epidemiology, clinical manifestations, risk reduction and treatment strategies of jaw osteonecrosis in cancer patients exposed to antiresorptive agents. *Future Oncol.* 2014 Feb;10(2):257-75.
2. A Coropciuc RG *et al.*. Medication-related osteonecrosis of the jaw in oncological patients with skeletal metastases: conservative treatment is effective up to stage 2. *Br J Oral Maxillofac Surg.* 2017 Oct;55(8):787-792.
3. Beth-Tasdogan NH *et al.*. Interventions for managing medication-related osteonecrosis of the jaw. *Cochrane Database Syst Rev.* 2017 Oct 6;10:CD012432.

### D04 - Stage III medication-related osteonecrosis of the posterior maxilla. Surgical treatment using a pedicled buccal fat pad flap: five case reports

F. M. Erovigni, A. Gambino, Monica Brega \*, M.Carossa, A. Dell'Acqua

*Università di Torino, CIR Dental School, Turin, Italy*

**BACKGROUND:** Stage III medication-related osteonecrosis of the jaw (MRONJ) sometimes requires surgical treatment for resolution of the pathology and, in many cases, leads to

oro-antral communication in the posterior maxilla. The buccal fat pad flap is considered the best surgical choice for closure of large oro-antral communications because it provides primary closure and guarantees adequate bone protection with sufficient blood supply for an effective bone healing process. **METHODS:** Five patients affected by stage III (SICMF-SIPMO) posterior maxillary MRONJ were treated with surgical removal of the necrotic bone and primary closure of the oro-antral communication using a buccal fat pad flap. In two cases Zoledronic acid was the only drug administered in both cases for breast cancer, whereas two underwent previous treatment with Zoledronic acid and current with Denosumab for lung and breast cancer respectively. One patient with osteoporosis with ibandronic acid.

**RESULTS:** In three cases, the size of the flap was always sufficient to perfectly close the defect without tension. There were no postoperative complications and the average post-operative hospital stay was 3 1 days. The patients were seen at 1-2-6 months follow-ups; after 12 months of follow-up, no problems were noted in the treated area. In a Zoledronic acid-Denosumab patient wound dehiscence and necrosis extension occurred, possibly due to incomplete necrotic bone removal; therefore, two different session of bone debridement were performed, at two weeks and six months after surgery. Similarly, the only osteoporotic was treated with the same approach, due to te occurrence of a fistula six months after the surgery. **CONCLUSIONS:** Despite the limited number of cases, the results of this study suggest that, for stage 3 posterior maxilla MRONJ, managing the site with a pedicled buccal fat pad flap and primary closure might guarantee adequate bone protection with sufficient blood supply for an effective bone healing process. Berrone *et al.* published a similar case series showing satisfying results, with none of the five patients experiencing recurrence of MRONJ after a buccal fat pad flap. Further studies are needed in order to assess the efficacy of this surgical protocol in larger group of severe MRONJ patients

#### REFERENCES:

1. Mattia Berrone, DDS, Filippo Umberto Florindi, DDS, Vincenzo Carbone, MD, DDS Stage 3 Medication-Related Osteonecrosis of the Posterior Maxilla: Surgical Treatment Using a Pedicled Buccal Fat Pad Flap: Case Reports
2. PAUL SCOTT, GILLON FABBRONI ,DAVID A. MITCHELL The Buccal Fat Pad in the Closure of Oro-Antral Communications: An Illustrated Guide Dental Update – July/August 2004
3. Jasmeet Singh, Kavitha Prasad, MDS, R. M. Lalitha, MDS, and K. Ranganath, MDS Buccal pad of fat and its applications in oral and maxillofacial surgery: a review of published literature (February) 2004 to (July) 2009 (*Oral Surg Oral Med Oral Pathol Oral Radiol Endod* 2010;110:698-705)

### D05 - Low-level laser therapy in the treatment of osteonecrosis of the jaws: prospective study

F. Ronzino\*, C. Moreschi, F. Cattoni, S. Abati, G. Gastaldi

*Clinical Unit of Oral Medicine and Pathology, Dept. of Dentistry, IRCCS, San Raffaele University Hospital, Milan, Italy*

We studied the Low-level Laser Therapy (LLLT), in addition to antibiotic therapy, as a conservative treatment of the osteonecrosis of the jaws, in patients not able for surgery, both for systemic disease and loco-regional complications. Our patients improved the life quality, determining, in the most part of the cases, the complete healing of the lesion. Our study was conducted at Vita Salute San Raffaele University

dental department, from January 2014. We recruited, for this study, 13 patients, 9 females and 4 males. The inclusion criteria were:

1. Bisphosphonate-induced osteonecrosis patients or radiotherapy-induced osteonecrosis patients
2. Patients with loco-regional complications
3. Patients with systemic disease, not able to surgery
4. Patients between 18 and 99 years

Exclusion criteria were:

- Patients selected for surgical treatment
- Patients undergoing an osteonecrosis treatment

An orthopantomography was prescribed to the patients to evaluate the extension of the necrotic area, during the first visit and the patients were asked to give a pain value, according to the VAS scale. Then each patient was included in the conservative osteonecrosis protocol, consisting in a medical therapy (Amoxicillin 1gr/cp, 1 cp twice a day for 14 days and Metronidazole 250 mg/cp, 2 cps twice a day for 14 days) and LLLT (1 application a week until the mucosal healing).

We removed the necrotic fragments that spontaneously fall off from the mucosal cavity and we applied LLLT 2 mm from the lesion. The procedure was repeated 5 time in the same session. Each patient had to undergo hygiene procedures and rinse with CHX at least 2 times a day. The healing was defined as:

- CR: complete response
- PR: partial response
- NR: non-response

The healing was evaluated comparing the pre-operative and post-operative photography, separately, by two expert clinicians. The patients were scheduled in a follow-up program, after the complete mucosal healing, to evaluate any relapse. We observed that osteoradionecrosis affected more male than female, on the other hand osteonecrosis induced by bisphosphonate affected more female than male (Chi-square= 5.31, p= .021). The relation between osteonecrosis and healing was not a significative data, because of the small number of patients. The pain of the patients decrease in relationship with the number of the LLLT application ( $t(13) = 12.50, p < .001$ ). The number of LLLT application was not related with pain reduction. In conclusion, LLLT, associated with antibiotics therapy, can be effective in the treatment of osteonecrosis of the jaws, in patients with systemic disease or loco-regional complications, with contraindication to surgery.

REFERENCES:

1. Epidemiology, clinical manifestations, risk reduction and treatment strategie of jaw osteonecrosis in cancer patients exposed to aantiresorptive agens. Capisi G. *et al.* Future Oncol.2014
2. Medication-Related osteonecrosis of jaws: a low-level laser therapy and antimicrobial photodynamic therapy case approach. Minamisako MC. *Et al.* Case rep Dent. 2016
3. Efficacy of laser therapy in the management of bisphosphonate-related osteonecrosis of the jaw (BRONJ): a systematic review. Weber JB, *et al.* Lasers Med Sci. 2016

**D06 - Hypothesis on the causes and on the care of osteonecrosis of the jaw in cancer patients treated with Bisphosphonates**

R. Ghiringhelli \*

??????

Mucoosteonecrosis of the jaw is a damage that is created in the oral cavity in a number of patients ranging from 1,2% to 9,9% that have been treated for a certain period with

Bisphosphonates. Bisphosphonates have the capacity to avoid the dissolution of dihydroxyapatite crystals, primary mineral constituent of bones. Derived from pyrophosphate, with the substitution of the P-O-P bridge with a non Hydro soluble P-C-P bridge, they are characterized by the fact they are constituted by only two phosphate group, from this characteristic the name Bisphosphonates. To this P-C.P bridge with two phosphate groups are connected two side chains, a long one to characterize the chemical properties, the activity and the course of action of the Pharmaceutical Substance (Pharmacodynamics), and a short one, which characterizes the chemical properties and the Pharmacokinetics of the Pharmaceutical Substance. The Bisphosphonates constitute a well known therapy for osteoporosis, Paget's Disease, Faulty Osteogenesis, bone metastasis in solid cancer or osteolysis from multiple myeloma, in order to prevent the SRE (Skeletal Related Events). The active pharmaceutical ingredient is designed to be highly selective, triggering only the inhibition action of the osteoclast.

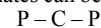
Bisphosphonates are classified in two categories

- NOT Aminobisphosphonates or not containing nitrogen
- Aminobisphosphonates or containing Nitrogen

Can we consider that Bisphosphonate is a caustic that, aims his action to the osteoclasts? The side-effects are: Osteonecrosis of the jaw bones - Gastritis, Esophagitis, Gastric ulcer - Kidney failure - Ocular Symptoms: conjunctivitis. Focusing our interest on osteonecrosis of jaw we conclude that it can be caused by both non-amino and amino Bisphosphonates. It appears immediately that kidney excretion working, ocular apparatus, stomatognathic system and gastro-esophagus apparatus are sprinkled by a double circulatory flood. The most reasonable hypothesis could be that Bisphosphonates can reach, in these districts, due to the contemporary action of the two circulatory streams, such high concentrations to lose their highly selective characteristic. The damage is formed when the intertissutal concentration reaches or exceed a defined level, causing the pathology to start. In case of jaw osteonecrosis from Bisphosphonates, the mechanisms of Pharmacologic neutralization must have a synergic action with the endogenic system of the target organism. We believe that oxidation could be a better process for our needs. We have to take into account two mechanisms: 1) Combustion (heat) 2) Vehiculation of Ozone (O3) in SITU

Ozone (O3 is toxic for oxidation, this gas, if well utilized could be very efficient for our aim. This activity is due to the activity of O Singlet. This active atom, is very reactive with C-C double bonds and for double bonds between carbon and other compounds.

This causes the break of the C-C bridges in not saturated lipids that also compose the cellular membrane and ignites a mechanism similar to the one due to ionizing radiations. The central nucleus of Bisphosphonates can be read with the formula:



On this bridges between carbon atoms and others the singlet of ozone acts with his capacity of Electron-suck, degrading the compound in the single residual components (oxidation). This gas, with his oxidizing action, separates Hydroxyapatite from Bisphosphonates and degradates the latter. Moreover Ozone with the correct dosage, increases the antioxidant reaction of our body (adapting to the oxidative stress). The high chemical reactivity of ozone is able, breaking the bond between calcium of hydroxyapatite and the near phosphonate group, to determine the removal of the compound and also his probable degradation.

## REFERENCES:

1. Migliorati CA, Schubert MM, Peterson DE, *et al.* Bisphosphonate-associated osteonecrosis of mandibular and maxillary bone: an emerging oral complication of supportive cancer therapy. *Cancer* 104:83-93, 2005 E ALTRI

### D07 - Early treatment of medication-related osteonecrosis of the jaws: comparison between surgical and non-surgical approach

G. Ghidini\*, M. Manfredi, M. Meleti, P. Vescovi

*Oral Medicine and Oral Surgery Laser Unit, University Center of Dentistry, Department of Medicine and Surgery, University of Parma, Parma, Italy*

**BACKGROUND:** Medication-related osteonecrosis of the jaws (MRONJ), is an adverse effect of several medications (e.g. bisphosphonates, anti-resorptive and anti-angiogenic monoclonal antibodies) used to treat bone metastases of solid tumours, multiple myeloma and other metabolic disorders. The use of laser technologies to improve bone and mucosal healing provides advantages in both surgical and non-surgical approaches. In addition to laser, early approach to MRONJ seems to lead to a higher probability of successful treatment. In the present study we compared 5 different therapeutic approaches to treat 191 sites of MRONJ. A distinction between sites in stage I and sites in stage II and III was applied. **METHODS:** One-hundred and ninety-one sites of MRONJ were treated between January 2004 and March 2018 at the Center of Oral Medicine and Laser Surgery of the Academic Hospital of University of Parma. Lesions were classified as Group 1 (G1): 83 (43,45%) sites of MRONJ stage I and as Group 2: (G2) 108 sites (56,55%) of MRONJ stage II and III. Twenty-four patients (28,91%) in G1 and 37 (34,26%) in G2 were male, 59 patients (71,09%) in G1 and 71 in G2 (65,74%) were female. Sixty-eight patients (81,93%) in G1 and 78 (72,23%) in G2 were treated for cancer and 15 patients (18,07%) in G1 and 30 (27,77%) in G2 were treated for non-neoplastic diseases. Twenty-two sites in G1 (26,5%) and 34 (31,48%) were localized in the maxilla; 61 (73,5%) in G1 and 74 (68,52%) in G2 in the mandible. Five different therapeutic approaches were evaluated and cross-compared between G1 and G2. Group A: 3 sites of G1 and 5 of G2 treated with medical therapy alone (amoxicillin + clavulanic acid, 1g every 12 hours and metronidazole 500mg every 12 hours). Group B: 27 for G1 and 31 for G2 sites treated with medical approach and LLLT application performed with Nd:YAG laser (1064nm FidelisPlus, Fotona-Slovenia, 1,25W, 15Hz), 1 session a week for 5 weeks. Group C: 7 for G1 and 3 for G2 sites treated with medical therapy and traditional rotary surgery. Group D: 11 for G1 and 32 for G2 sites treated with medical therapy, traditional rotary surgery and LLLT. Group E: 35 for G1 and 36 for G2 sites treated with medical therapy, Er:YAG Laser surgery (2940nm FidelisPlus, Fotona-Slovenia, 250mJ – 20Hz -VSP- Fluence 50J/cm<sup>2</sup>) and LLLT. We took into consideration 2 outcomes: clinical improvement, from a higher stage to a lower one (clinical improvement - CI), and regression to Stage 0 (complete healing - CH). The statistical analysis was performed using the Pearson's chi<sup>2</sup> test. The probability to commit an alpha-type error of less than 5% was considered significant.

**RESULTS:** No statistically significant results were found comparing G1 and G2 in Group A, C, and D both for CI and CH (A:p=0.1071 and 1, C:P=1 and 0,3, D:p=0,4507 and 0,4066). A p value of 0,013 (significant) was found for CI for

Group E and a p value extremely significant (p<0.0001) was found for CH in Group B.

**CONCLUSIONS:** According to the present study, LLLT reduces pain and decrease suppuration in case of MRONJ. LLLT can also be used as adjuvant therapy after surgical removal of necrotic bone. Early stage approach seems to significantly improve treatments outcome. Our study shows how an early stage treatment improves outcomes for non-surgical treatment. In the present study, statistical significance was not highlighted for surgical treatment options because of the high success rate even for severe stages of MRONJ. However, it should be borne in mind that treatment of severe stages often imply longer post-operative healing periods and higher general discomfort and pain for patients.

## REFERENCES:

1. American Association of Oral and Maxillofacial Surgeons. Medication- Related Osteonecrosis of the Jaw- 2014 Update. *J Oral Maxillofac Surg*, 2014.

### D08 - Peculiarities and problems in the resective and reconstructive treatment of bisphosphonate mandibular osteonecrosis

A. Manfuso, C. Copelli, K. Tewfik, R. Cocchi

*Operative Unit of Maxillo-Facial Surgery, Otolaryngology and Dentistry. IRCCS Casa Sollievo della Sofferenza, San Giovanni Rotondo (FG), Italy*

The surgical treatment of bisphosphonate osteonecrosis is still a controversial topic and it is often difficult to define the best treatment option. Although numerous recommendations have been made for treatment involving nonsurgical therapy, the resective treatment still remains the main choice in a selected group of patients with massive extension of the pathology. There are several factors that make these patients particularly problematic: the state of the soft and bone residual tissues, the general clinical conditions, the long antibiotic therapies performed, any previous surgical courtage, the doubts about the prognosis of patients who carry out treatment for oncologic diseases. Moreover the doubt if to reconstruct and the decision about the kind of reconstruction often raises doubts about the actual benefits of often long and invasive procedures. In particular, current treatment guidelines caution against osseous reconstruction using free flap tissue to treat bisphosphonate-related osteonecrosis of the jaw (BRONJ). The primary rationale for this stance is the theoretical risk of nonunion and recurrence of disease within the reconstruction. The Authors present their experience with patients who have undergone mandibular resection for BRONJ from 2011 to 2017 at the Operative Unit of Maxillo-Facial Surgery of the IRCCS Casa Sollievo della Sofferenza. The problems, reconstructive choices, complications, post-operative course and follow up of the treated patients will be analyzed. The results will be compared with those reported in the literature in order to demonstrate that resection of BRONJ permits acceptable healing in patients taking bisphosphonate medication, with high degree of success.

## REFERENCES:

1. Kim HY, Lee SJ, Kim SM, Myoung H, Hwang SJ, Choi JY, Lee JH, Choung PH, Kim MJ, Seo BM. Extensive Surgical Procedures Result in Better Treatment Outcomes for Bisphosphonate-Related Osteonecrosis of the Jaw in Patients With Osteoporosis. *J Oral Maxillofac Surg*. 2017 Jul;75(7):1404-1413.
2. Neto T, Horta R, Balhau R, Coelho L, Silva P, Correia-Sá I, Silva A. Resection and microvascular reconstruction of bisphosphonate-related osteonecrosis of the jaw: The

role of microvascular reconstruction. *Head Neck*. 2016 Aug;38(8):1278-85.

- Carlson ER, Basile JD. The role of surgical resection in the management of bisphosphonate-related osteonecrosis of the jaws. *J Oral Maxillofac Surg*. 2009 May;67(5 Suppl):85-95.

### **D09 - Conservative surgical treatment of medical related osteonecrosis of the jaw: experience of a single institution**

M. Nisi, S. Mariotti, M. Gabriele

*Department of Surgical, Medical and Molecular Pathology and Critical Care Medicine, University of Pisa, Pisa, Italy*

**BACKGROUND:** Medication-related osteonecrosis of the jaw (MRONJ) is a side effect of antiresorptive medications (IV and oral BPs, rank ligand inhibitor like denosumab) and antiangiogenic medications. The management of medical related osteonecrosis of the jaw has not been completely elucidated, and its treatment can vary from no or limited surgery to more extensive surgery. Aim of the present study was to evaluate the efficacy of localized surgical treatment of MRONJ lesions in a cohort of patients referred to the unit of Odontostomatology and Oral surgery of the University of Pisa.

**METHODS:** The study included all consecutive subjects diagnosed with MRONJ that had undergone localized surgery in the Department of Dentistry and Oral Surgery of the University Hospital of Pisa from January 2004 to December 2017. Diagnosis of MRONJ was made according to the criteria of the American Association of Oral and Maxillofacial Surgeons. Data on demographic, health status, type and duration of antiresorptive medication and osteonecrosis characteristics were collected retrospectively. The primary outcome was a complete healing of MRONJ lesion.

**RESULTS:** Two hundred and forty three patients, with 256 MRONJ lesions, were identified and included in the present study (174 females; mean age 68,85 years; SD 10.7 years). 176 patients (72,4%) received intravenous bisphosphonates (zoledronic acid 4mg IV) for the treatment of oncologic pathologies: metastatic breast cancer (72 patients, 29,6%), multiple myeloma (44 patients, 18,1%), kidney cancer (5 patients, 2,1%) and metastatic lung cancer (17 patients, 7%). Sixty-four patients (26,3%) received bisphosphonates for the treatment of osteoporosis. Three patients (1,2%) received Denosumab for the treatment of metastatic breast cancer. The MRONJ lesions were mainly symptomatic (241 lesions, 94,1%) and bone exposure was detectable in the vast majority of cases (203 lesions, 79,3%); pus was detected in 93% of cases (237 lesions). 173 lesions were located in the mandible. The main event leading to MRONJ was dental extraction (142 lesions, 55,5%), periodontal/perimplant disease (24 lesions, 9,4%), prosthetic trauma (42 lesions, 16,4%), odontogenic infection (21 lesions, 8,2%) and dysodontiasis of third molar (2 lesions, 0,8%). The most frequent stage of MRONJ was stage II (137 subjects, 14,5%), whereas stage I (37 subject, 14,5%), and stage III (82 subject, 32%) were less common. 175 patients show complete healing after surgical treatment. However, sixty-eight (22,7%) do not completely recuperate and required further surgical management to treat the relapsed lesion. Stratification indicated 94.3% total disease resolution for all stage I lesions, 78.9% of improvement for stage II and 51.7% for stage III.

**CONCLUSIONS:** Our data suggest that patients with MRONJ lesions may benefit from local surgical treatment. Patients with severe MRONJ stage seem to present an increased risk of surgical treatment failure.

### **REFERENCES:**

- Kim HY, Lee SJ, Kim SM, Myoung H, Hwang SJ, Choi JY, Lee JH, Choung PH, Kim MJ, Seo BM. Extensive Surgical Procedures Result in Better Treatment Outcomes for Bisphosphonate-Related Osteonecrosis of the Jaw in Patients With Osteoporosis. *J Oral Maxillofac Surg*. 2017 Jul;75(7):1404-1413.
- Shintani T, Hayashido Y, Mukasa H, Akagi E, Hoshino M, Ishida Y, Hamana T, Okamoto K, Kanda T, Koizumi K, Yoshioka Y, Tani R, Toratani S, Okamoto T. Comparison of the prognosis of bisphosphonate-related osteonecrosis of the jaw caused by oral and intravenous bisphosphonates. *Int J Oral Maxillofac Surg*. 2015 Jul;44(7):840-4.
- Ruggiero SL, Kohn N. Disease Stage and Mode of Therapy Are Important Determinants of Treatment Outcomes for Medication-Related Osteonecrosis of the Jaw. *J Oral Maxillofac Surg*. 2015 Dec;73(12 Suppl):S94-S100.

### **D10 - MRONJ: presence of suppuration as a prognostic factor for surgical interventions**

M. G. Campolongo\*, M. Val, R. Marino, M. Pentenero

*Department of Oncology, Oral Medicine and Oral Oncology Unit, University of Turin, Orbassano, Italy*

Medication-related osteonecrosis of the jaw (MRONJ) is a severe side effect of anti-resorptive and anti-angiogenic therapy, that may get worse the quality of life of oncological patients affected. In presence of ONJ, treatment is needed to limit the disease and mainly to improve the quality of life of patients. Therefore clinicians need objective parameters in order to choose a tailored treatment for oncological patients with ONJ. The primary aim of this study is to evaluate the prognostic role of suppuration for stage I ONJ with indication to surgical debridement. The secondary aim is to evaluate the time to onset of relapse with reference to the treatment performed. From January 2010 to January 2018, 396 patients treated with anti-resorptive or anti-angiogenic drugs were followed-up in the oral surgery and medicine department of San Luigi Gonzaga hospital of Orbassano (Turin): 54 (13.6%) subjects had a diagnosis of osteonecrosis of jaws. The choice of treatment was based on the clinical stage of ONJ and on the performance status of patients. Most of patients (40/54; 74%) had indication to a surgical approach: debridement in 27 patients (50%), marginal or segmental surgery in 13 patients (25%). Medical treatment was performed in 7 subjects (13%) and 7 patients (13%) did not have any treatment because of poor performance status or because they refused treatment. Surgical debridement was performed just in patients with a stage 1a/1b ONJ (SICMF-SIPMO staging system). Relapse was observed in 11/27 (41%) patients with a mean free of disease interval of 106 days. In absence of suppuration (12 stage 1a patients), no relapse was observed; in presence of suppuration (stage 1b), relapse was observed in 11 out 15 (73%) patients with an average free of disease interval of 106 days. Marginal resective surgery was performed in 10 patients (2 stage 1a patients, 7 stage 1b patients and 1 stage 3 patient). Relapse was observed in 2/10 (20%) patients with a mean free of disease interval of 92 days. Both these 2 patients had suppuration at diagnosis (stage 1b). Segmental resective surgery was performed in 3 patients (2 stage 2b patients, 1 stage 3 patient). Relapse was observed in 2/3 (66%) patients with a mean free of disease interval of 720 days. These 2 patients had suppuration at diagnosis (1 stage 2b and 1 stage 3). Suppuration seems to be a negative prognostic factor for surgical interventions of ONJs. Of utmost interest, when the extension of ONJ supports a surgical debridement, the presence of suppuration seems to



be a significant predictive factor for relapse ( $p < 0.0001$ ), to be expected about 3 months after surgery. These evidences suggest to add the presence of suppuration as an important factor to guide the choice of a tailored treatment in order to improve the quality of life of oncological patients affected from ONJ. The choice of tailored treatment in patients with ONJ apparently manageable through conservative surgical debridement, should also be guided by the prognosis of patients and by the presence of suppuration.

## REFERENCES:

1. Beth-Tasdogan, Natalie H., Benjamin Mayer, Heba Hussein, and Oliver Zolk. "Interventions for Managing Medication-Related Osteonecrosis of the Jaw." *The Cochrane Database of Systematic Reviews* 10 (06 2017)
2. Favia, G., A. Tempesta, L. Limongelli, V. Crincoli, and E. Maiorano. "Medication-Related Osteonecrosis of the Jaw: Surgical or Non-Surgical Treatment?" *Oral Diseases* 24, no. 1-2 (March 2018): 238-42.
3. Oteri, Giacomo, Francesco Saverio De Ponte, Michele Runci, Matteo Peditto, Antonia Marciànò, and Marco Cicciù. "Oral-Health-Related Quality of Life After Surgical Treatment of Osteonecrosis of the Jaws." *The Journal of Craniofacial Surgery* 29, no. 2 (March 2018)

### D11 - B.P.F.C.® Bio-Plasma® with Pure Growth Factors (BioPlasma®) for the treatment of maxillary osteonecrosis, related to bisphosphonates (BRONJ)

R. Viganò<sup>1</sup>, L. Viganò<sup>2</sup>, C. Casu<sup>3</sup>

<sup>1</sup>Freelance, Varese, Italy; <sup>2</sup>University of Milan, Department of Radiology, Milan, Italy; <sup>3</sup>Private Dental Practice, Cagliari, Italy

**BACKGROUND:** The aim of this study was to evaluate the efficacy of a new platelet-rich plasma preparation and its regenerative capacity of Bone Tissue (GBR) and Soft Tissues (GTR), for the treatment of maxillary osteonecrosis, related to bisphosphonates (BRONJ) using a pure platelet concentrate. This is made without the use of anticoagulant nor any type of activator eg: bovine thrombin, calcium chloride. For this reason it has been called "Pure", it is the B.P.F.C.® Bio-Plasma® with Pure Growth Factors (BioPlasma®) designed and developed by Dr. Raffaello Viganò (Varese Italy 2010), to promote the healing process in patients with BRONJ.

**METHODS:** 35 patients (8 men, 27 women, aged 45-89 years) with a clinical and radiographical diagnosis of BRONJ were enrolled in this study. The patients were observed during a period of 4 years. They are treated with a regenerative surgical procedure using a rich BioPlasma® preparation with Pure Growth Factors. All patients have read and signed a written consent form. The study protocol was approved by the Ethics Committee for Human Studies of the "Ospedale di Circolo" - University of Varese, and was conducted in accordance with the 1975 Helsinki Declaration, amended in 2000. The phases of the study were: taking blood from the patient with Vacuette 9 ml; centrifugation and fractionation of the blood material; creation of the membrane with a mixture of fibrin and poor plasma; preparation of rich gelled plasma and placement at the osteonecrotic site (after bone sequestration removal); positioning of the membrane above the rich plasma; final suture with minimal exposure of the membrane.

**RESULTS:** After a BRONJ diagnosis no patient discontinued the use of BPs only because of the need for surgery. No intraoperative or postoperative complications were observed,

and all 35 BRONJ patients were successfully treated. Patients were observed for the next 6 months without showing relapses.

**CONCLUSIONS:** Our data showed how the preparation of Bio-Plasma® with Pure Growth Factors, inserted in the bone cavity of patients with a diagnosis of BRONJ, associated with the use of fibrin enriched with poor Plasma as a suturing membrane is able to provide perfect healing with the integrity of the hard and soft tissue after 6 months. The membrane made with a fibrin and poor plasma is very important for the protection of the surgical site from penetration bacteria. Further studies, such as randomized clinical trials, are needed to validate these results with a larger sample size and longer follow-up time.

### D12 - Effect of leukocyte and platelet-rich fibrin (L-PRF) on the treatment of BRONJ

V. Zavaglia<sup>1</sup>, A. Nori<sup>1</sup>, M. Mascitti<sup>2</sup>, A. Tesi<sup>1</sup>, A. Santarelli<sup>2</sup>

<sup>1</sup>Special and Surgical Stomatology Department, "Ospedali Riuniti" Hospital of Ancona, Ancona, Italy. <sup>2</sup>Department of Clinical Specialistic and Dental Sciences, Marche Polytechnic University, Ancona, Italy

**BACKGROUND:** Bisphosphonate-related osteonecrosis of the jaw (BRONJ) is a potential complication resulting from the long-term therapy with bisphosphonates. The presence of all the following characteristics may indicate that the patient is affected by BRONJ: current/previous therapy with bisphosphonates; exposed bone or bone that can be probed through a fistula in the maxillofacial region that persists for more than 8 weeks; no history of head and neck radiotherapy or metastatic disease to the jaws. To date, the management of BRONJ remains challenging due to the absence of definitive treatment other than palliative therapies. The application of leukocyte and platelet-rich fibrin (L-PRF) in the surgical site may constitute an alternative method of BRONJ treatment. The use of platelet concentrates in oral surgery has been reported in several studies, showing positive effects in bone regeneration and soft tissue healing. Recently, several studies have explained that the L-PRF had a role in the management of BRONJ. The aim of this study is to describe the clinical features and to evaluate the L-PRF treatment outcomes in a group of patients with BRONJ.

**METHODS:** In this mono-institutional prospective study, 15 consecutive patients with BRONJ were enrolled. All the patients presented a history of zoledronate therapy and a confirmed diagnosis of BRONJ. As regards the therapy, the patients were randomly divided in two groups: in the first one (Group 1) patients received "standard therapy" (0.12% chlorhexidine digluconate mouthwash, local irrigation, systemic antibiotics, minimally-invasive surgical procedures), while patients on Group 2 received the same therapy with the use of L-PRF in the surgical procedure. Demographic and clinical data were recorded. Follow-up consists in regular clinical and radiological evaluation at days 10, 30, months 2, 4, 6, 8, 10, and 12, to ascertain the absence of recurrences. The observed number of recurrences were compared between the two groups.

**RESULTS:** 15 patients with BRONJ were selected (8 patients in Group 1 and 7 in Group 2). Our patients showed a mean age of  $66.2 \pm 10.5$  years (63.6 and 69.3 years in Groups 1 and 2, respectively), with a mean zoledronate administration time of  $37.6 \pm 14.2$  months. As regards the staging, 6 cases were Stage 1, 6 cases in Stage 2, and 3 in Stage 3. The lesions were predominantly located in the mandible ( $n = 9$ ). 2 cases

of recurrent BRONJ were observed in Group 1, and 1 case in Group 2. Regarding recurrence risk, no statistical differences were observed in the studied groups.

**CONCLUSIONS:** For prevention of BRONJ recurrences, the use of L-PRF is an alternative treatment modality that may be effective for the coverage of exposed bone and soft tissue healing in BRONJ patients. More extensive studies will be required to determine the efficacy of this method.

**REFERENCES:**

1. Kim JW, *et al.* Leucocyte-rich and platelet-rich fibrin for the treatment of bisphosphonate-related osteonecrosis of the jaw: a prospective feasibility study. *Br J Oral Maxillofac Surg.* 2014.
2. Gönen ZB, *et al.* Treatment of bisphosphonate-related osteonecrosis of the jaw using platelet-rich fibrin. *Cranio.* 2017.

**CASE SERIES**

**E01 - SPECT-CT vs. CT in identifying MRONJ-affected bone. Correlation with surgical and histopathological findings. Preliminary results**

L.Basano <sup>1\*</sup>, F. Della Ferrera <sup>1</sup>, G. Brusasco <sup>2</sup>, M. Luciani <sup>1</sup>, P. Appendino <sup>1</sup>

<sup>1</sup>Dentistry and Oral Surgery Department, Turin, Italy; <sup>2</sup>Nuclear Medicine Department, Mauriziano Hospital, Turin, Italy

**BACKGROUND:** MRONJ (Medication related osteonecrosis of the jaws) is a significant health threat due to several medicaments. CT (Computed Tomography) is considered the main diagnostic radiologic examination<sup>1</sup>; SPECT-CT (single photon emission computed tomography/CT) was found to be effective in the localization and definition of the extension of MRONJ as well <sup>2,3</sup>.

**AIM:** Assessing usefulness and diagnostic accuracy of SPECT-CT compared to CT in the preoperative evaluation of patient requiring surgical treatment for MRONJ.

**METHODS:** Patients referring to Dentistry and Oral Surgery department with a clinical suspicion of MRONJ underwent SPECT-CT during diagnostic and preoperative evaluation. MRONJ was diagnosed and classified according to criteria by AAOMS and SICMF-SIPMO classifications<sup>1</sup>. Intraindividual correlations between SPECT-CT vs CT findings (CT images before SPECT fusion) and between these examinations vs surgical (extension) and histopathological (final diagnosis) conclusions were assessed by two nuclear physician/radiologist and three oral surgeons with a 4 grade-scale correspondence analysis (0: no correspondence, 1: underestimation, 2: overestimation, 3: full correspondence).

**RESULTS:** 15 (4♂, 11♀ mean age 72.6) consecutive patients were included. There were 12 (80%) oncologic patients (mainly breast cancer); mean duration of zoledronic acid and denosumab was 20.4 and 5.7 months respectively. Three patients received oral bisphosphonates for osteoporosis for several years (>5ys). Main apparent trigger was tooth extraction (80%). AAOMS and SICMF-SIPMO stages were 0/1/2/3 in 2/3/8/2 and 1/2/3 in 6/7/2 cases respectively with a prevalence of symptomatic presentation (86.6%). SPECT-CT uptakes were consistent with preoperative clinical signs in all cases if they were present. In two cases the uptakes anticipated development of clinical manifestation of MRONJ. An increased uptake in the same region of subsequent MRONJ was already

reported in previous bone scans in one patient. With respect to surgical findings, SPECT-CT showed an higher degree of correlation compared to CT (full correspondence %: 87.5%; 31.3% respectively). Correlation with histopathological conclusions was similar (SPECT-CT & CT 93.7%). Considering extension of nuclear/radiological signs consistent with MRONJ in both examinations, CT was found to underestimate the supposed extension of MRONJ compared to SPECT-CT (underestimation % 29.4 %); this confirming higher correlation with surgical findings (reference standard) of the latter.

**CONCLUSIONS:** SPECT-CT was found to be effective and superior to CT alone in defining the extension of MRONJ in diagnostic and preoperative phase especially in cases where only early unspecific CT signs were present, resulting in appropriate surgical management. Improved integration of morphologic information with data from metabolic activity in the region of interest seems to have overcome the poor specificity often attributed to nuclear bone imaging<sup>3</sup>. As SPECT-CT is frequently performed in oncologic patients for cancer staging it might be an useful diagnostic tool in the evaluation of patient at risk or with suspected MRONJ. Its efficacy in defining MRONJ-affected bone suggests that could be suitable also in osteoporotic patients with established MRONJ.

**REFERENCES:**

1. Bedogni A. *et al.* "Learning from experience. Proposal of a refined definition and staging system for bisphosphonate-related osteonecrosis of the jaw (BRONJ)". *Oral Diseases* (2012) 18, 621–623
2. Dore F. *et al.* "Bone Scintigraphy and SPECT/CT of Bisphosphonate-Induced Osteonecrosis of the Jaw". *J Nucl Med* 2009; 50:30–35
3. Bolouri C. *et al.* "Performance of orthopantomography, planar scintigraphy, CT alone and SPECT/CT in patients with suspected osteomyelitis of the jaw" *Eur J Nucl Med Mol Imaging* (2013) 40:411–417

**E02 - Radiological differences among ONJ patients affected from ONJ and negative patients under use of endovenous bisphosphonates**

C. Bianchi, F. Erovigni, F. Esposito, M. Floreno\*, S.D. Bianchi  
*CIR Dental School, Università degli Studi di Torino, Turin, Italy*

**BACKGROUND:** Bisphosphonate-related osteonecrosis of the jaws (BRONJ) is mainly observed in patients with multiple myeloma and bone metastases receiving i.v. bisphosphonate therapy. The inhibition of physiologic bone remodeling and angiogenesis by these potent drugs impairs the regenerative capacity of the bone, causing the development of BRONJ.

**OBJECTIVE:** The aim of this study is to evaluate differences in bisphosphonate-related radiological signs between the patients who develop BRONJ and those who don't.

**METHODS:** Forty patients affected by cancer and exposed to i.v. BF (zoledronate) therapy between 2008 and 2017 were selected on the basis of the availability of at least two CBCT exams, one of which performed immediately before or within six months from the beginning of BF treatment, to be considered as a baseline reference for the comparison to the subsequent possible changes revealed by the following exams. Patients were divided in Group ONJ+ if they had received diagnosis BRONJ and in Group ONJ- if they had no history of osteonecrosis. CBCT images were analyzed for the following signs: presence or evolution of cortical bone erosion;

sequestrum; periosteal reaction; thickening of cortical bone, of the mandibular canal or of lamina dura; grade of sclerosis of the spongy bone and its distinction from the cortical bone. RESULTS: In group ONJ+ 17/20 patients developed osteosclerosis. Increase in bone density was found both in patient who continued BF therapy and in those who suspended it. In 3/13 patients who developed an increasing osteosclerosis and stopped the BF therapy for long time (3 years or more) a regression of osteosclerosis with a return to a nearly normal appearance of the trabecular bone was noticed in the last CBCT. Cortical bone erosion was found in 17 patients, sequestrum in 16, periosteal reaction in 4, thickening of cortical bone in 1, prominence of inferior alveolar canal in 11 cases (out of 16 mandibles affected), thickening of the lamina dura in 16 patients. In group ONJ-, successive images didn't show the presence of the researched signs, revealing themselves almost superimposable to the baseline images.

CONCLUSIONS: In this study the availability of time 0 CBCT exam allowed to better understand the radiological evolution of pathological aspect of BRONJ and specially to separate the bone features before the BF treatment and their changes in time, more likely related to BF, which is a very important item in the evaluation of the "questionable" stage 0. The study confirms most of the radiological features of BRONJ: osteosclerosis, sequestrum and cortical bone erosion. It has been found that thickening of the lamina dura and prominence of inferior alveolar nerve canal are less frequent and that periosteal reaction is related to a more advanced BRONJ stage. For the first time a regression of the osteosclerosis has been identified, possibly related to the suspension of the BF treatment. In patients who don't develop BRONJ, it appears that the sole BF therapy doesn't induce significant radiological changes. This result would suggest the relocation of stage 0 of BRONJ to a previous phase, thus considering the sole spongy bone sclerosis as an initial sign of the development of osteonecrosis.

#### REFERENCES:

1. Ficarra G, Beninati F. Bisphosphonate-related Osteonecrosis of the Jaws: An Update on Clinical, Pathological and Management Aspects.
2. Ruggiero SL, Dodson TB, Fantasia J, Goodday R, Aghaloo T, Mehrotra B, *et al.* American Association of Oral and Maxillofacial Surgeons position paper on medication-related osteonecrosis of the jaw--2014 update.
3. Bianchi SD, Scoletta M, Cassione FB, Migliaretti G, Mozzati M. Computerized tomographic findings in bisphosphonate-associated osteonecrosis of the jaw in patients with cancer.

### E03 - Validation of prognostic impact of CT in medication-related osteonecrosis of the jaw: a longitudinal study

N. Salimian <sup>1\*</sup>, G. Bettini <sup>1</sup>, R. Motta <sup>2</sup>, S. Vio <sup>3</sup>, G. De Conti <sup>3</sup>

<sup>1</sup>Regional Center for Prevention, Diagnosis and Treatment of Medication and Radiation-related Bone Diseases of the Head and Neck, Padua, Italy; <sup>2</sup>University Hospital of Padua, Department of Medicine (DIMED), Institute of Radiology, Padua, Italy; <sup>3</sup>University Hospital of Padua, Department of Radiology, Padua, Italy

BACKGROUND: The knowledge of medication related osteonecrosis of the jaw (MRONJ) has developed gradually from its first report in 2003. Scientists all around the world have not still accepted a unique definition, diagnosis and staging. American Association of Oral and Maxillofacial Surgery (A.A.O.M.S.) defines MRONJ with its most common clinical

manifestations and bases its staging on clinical parameters mainly. In 2013 an expert comity at the Italian National Society of Maxillofacial Surgery - Italian Society of Pathology and Oral Medicine (SICMF-SIPMO) proposed a staging system founded on both clinical and radiological parameters, and conveyed a central role to Computed Tomography Scan in pathological process. However, including a radiological study predicts better the extent of bone disease but it still needs further valuations<sup>2,3</sup>. We evaluated clinical and radiological parameters and observed the existence of relevant clinical variables with positive or negative influences on the osteonecrosis of the jaw's progression. We hypothesized that basic disease and antiresorptive (AR) therapy suspension may both influence and progress osteonecrosis of the jaw. The ethics committees of the University Hospital of Padova (Prot. n°2693P; Prot. n°2584P) and University and Hospital Trust of Verona (Prot. n°2202; Prot. n°2106) approved the study and ' consent to participate was obtained where specifically required.

METHODS: We conducted a retrospective, longitudinal study on a prospective cohort of patients affected by medication-related osteonecrosis of the jaw at the Maxillofacial Surgery Unit of the University of Padua and Verona from January 2005 to September 2017. We enlisted patients diagnosed with MRONJ, without undergoing any previous resection surgery that may in somehow modify the clinical picture. We assessed patients with at least three clinico-radiological evaluations in minimum three-month intervals and created one-year history disease for each patient by collecting clinical information from their clinical data base and radiological data from their Computed Tomography Scans, which were independently evaluated by three experienced radiologists (double blind).

RESULTS: In this study we included a total of ninety patients, seventy-one cancer patients and nineteen patients with osteometabolic diseases. At the time of recruitment fifty-four patients had the AR therapy already waived and thirty-six were still on AR medications for another six months at least. We observed a pejorative clinical and radiological progression of MRONJ in cancer patients than non-cancer patients (osteometabolic bone diseases), who usually have a better prognosis. Cessation of AR medications did not influence the radiological parameters of disease at CT; and the bone disease seemed to progress independently. Comparing these two subpopulations, we detected some clinical parameters that seemed to be mostly related to routine cancer therapies of patients.

CONCLUSIONS: We showed that the patients underlying disease influences the progression of MRONJ rather than discontinuation of antiresorptive medication; and also illustrated that clinical progression differs from radiological progression so that Computed Tomography Scan becomes fundamental to evaluate and to prognosticate the disease.

#### references:

1. Bedogni, A., Campisi, G., Fusco, V., Agrillo, A. "Raccomandazioni clinico-terapeutiche su osteonecrosi delle ossa mascellari associata a bisfosfonati e sua prevenzione" (C.L.E.U.P., Versione 1.1; Marzo 2013).
2. Bedogni, A., Fedele, S., *et al.* Staging of osteonecrosis of the jaw requires computed tomography for accurate definition of the extent of bony disease. *Br J Oral Maxillofac Surg.* 2014, Vol. 52, Issue 7, p. 603-608.
3. Bagan J.V., Cibrian R.M., *et al.* Sclerosis in bisphosphonate-related osteonecrosis of the jaws and its correlation with the clinical stages: study of 43 cases. *Br J Oral Maxillofac Surg.* 2015, Vol. 53, Issue 3, p. 257-262.

### E04 - Role of nuclear medicine imaging techniques in early diagnosis of ONJ in prostate cancer patients: report of a demonstrative case

L. Tommasi \*, A. Fasciolo, V. Fusco, L. Benzi, A. Muni

*Nuclear Medicine Unit, Maxillofacial Surgery Unit, Oncology Unit, Radiology Dept. and "Centro Documentazione Osteonecrosi", Azienda Ospedaliera "SS. Antonio e Biagio e C. Arigo", Alessandria, Italy*

**BACKGROUND:** Nuclear Medicine imaging techniques, i.e. planar bone scan (Tc99 m scintigraphy) and PET (Positron Emission Tomography) with several tracers, have been suggested as useful aids to diagnosis of Osteonecrosis of Jaw (ONJ), that is mostly based on clinical observation (signs and symptoms, with/without bone exposure) and Computed Tomography (CT) scan. A potential advantage of Nuclear Medicine techniques is that of detect ONJ very early (due to precocious uptakes), especially in ONJ cases without frank bone exposure.

**CASE REPORTS:** On December 2016, a 63-year prostate cancer patient was referred to our Multidisciplinary ONJ Team due to maxillary and mandible teeth mobility, without bone exposure or pain. He had received zoledronic acid (for 24 months) and then denosumab (for 48 months) between 2010 and 2016. A CT scan revealed : a) diffuse osteosclerosis of mandible; b) lytic alteration of right hemimandible (mostly 4.6 region); c) localized areas of periosteal thickening to both right and left side; d) osteosclerosis of left maxillary bone; e) fullness of left maxillary sinus; g) defect of nasal wall of left maxillary sinus; f) minimum alteration of right maxillary sinus. Post-hoc review of two previous planar bone scans revealed (beside diffuse skeletal uptakes due to metastatic lesions) jaw uptakes. On the exam of July 2015: slight uptake at right hemimandible; on that one of March 2016: uptakes on left maxillary bone, right hemimandible (limited to angle), left hemimandible (more extended), all of them not specifically reported by nuclear medicine specialist. Furthermore, a post-hoc revision of a 18F-Choline PET-CT (performed on April 2016) revealed tracer uptakes on the three involved quadrants (left maxilla; right and left mandible). On the basis of December 2016 CT scan, the final diagnosis was of three areas of ONJ, all of them "stage 0" according to AAOMS and one stage 1 (maxillary) and two stage 2 (right and left mandible) according to SIPMO-SICMF staging system. During the follow-up of the case, two other exams were performed.

On May 2017, a new 18F-Choline PET (requested by the patient's oncologist to evaluate extra-skeletal disease) showed frank uptakes in the three involved quadrants ; CT images revealed beginning sequestration in the areas, more evident at maxilla and right mandible sites. On July 2017, a SPECT/CT (Single Photon Emission Computed Tomography with associated CT scan) of maxillary and mandible regions confirmed the three ONJ foci; at the combined CT images the bone was radiolucent with nuclear inclusion compatible with sequestrum at all the sites. Some months later, a bone fragment was expelled at the left maxilla.

**DISCUSSION:** This case apparently suggests that several and different Nuclear Medicine imaging techniques (requested to evaluate cancer diffusion) are a possible aid to diagnosis of ONJ cases. Not only planar bone scan showed to be more sensible (even if not specific) than CT scan in early depicting ONJ areas, but also 18F-Choline PET-CT (that recently

in many cases superseded the combination of bone scan and CT scan in management and evaluation of prostate cancer patients) might be helpful (this is the first report in literature and it is to be confirmed). Finally, SPECT/CT with maxillary and mandible study seems an outweigh instrument to study ONJ cases, when available. The importance of clinical and drug history information for Nuclear Medicine specialist is to be underlined.

#### REFERENCES:

1. Fusco V, Muni A, Rouhanifar H, Greco B, Tommasi L. Is bone scan (Tc99 scintigraphy) uptake predictive of clinical onset of osteonecrosis of jaw (ONJ)? *Ann Stomatol (Roma)* 2014 Apr-Jun; 5(2 Suppl): 11. Published online 2014 May 9. PMID: PMC4377671
2. Thomas C, Spanidis M, Engel C, *et al.* Bone scintigraphy predicts bisphosphonate-induced osteonecrosis of the jaw (BRONJ) in patients with metastatic castration-resistant prostate cancer (mCRPC). *Clin Oral Investig.* 2016 May;20(4):753-8.

### E05 - Oral bisphosphonates; patients' lack of knowledge could increase MRONJ risk. Surgical management improved with the aid of SPECT-CT

F. Della Ferrera \*, L. Basano, A. Galiotti, L. Guaschino, P. Appendino

*Dentistry and Oral Surgery Department, Mauriziano Hospital, Turin, Italy*

**BACKGROUND:** Nowadays little is known about the awareness of MR-ONJ (Medication Related-Osteonecrosis of the Jaws) risk among health care professionals (HCP) and patients treated with oral bisphosphonates (oBP) for osteoporosis. The outbreak of MRONJ among oncologic patients resulted in increased HCP and patient awareness with considerable diffusion of preventive guidelines. In particular the preventive oral health management is recommended since before the beginning of antiresorptives<sup>1</sup>. No clear recommendations are provided regarding oral health prevention before the beginning of oBP due to the lower MR-ONJ risk among osteoporotic patients<sup>2</sup>. Existing guidelines discuss their dental management after 4 years of antiresorptive therapy<sup>1</sup>. This along with poor information of patients about their medications and their adverse effects can result in unreporting oBP consumption, being another risk factor for MR-ONJ.<sup>3</sup>

**CASE REPORT:** S.M. 84 y/o, declared taking losartan, amlodipin and atorvastatin for cardiovascular disease prevention and zolpidem for insomnia. On October 2016 presented to her private dentist with signs and symptoms of apical periodontitis of 4.7. An intraoral x-ray revealed a periapical osteolysis of the mesial root. Root canal treatment (RCT) of 4.7 was performed. Two months later, no radiological reduction of the osteolytic lesion was observed. The dentist therefore decided to perform rizotomy of the mesial root of 4.7 where the osteolytic lesion was more evident. On March 2017 the tooth was extracted because of the expansion of the osteolysis under distal root of 4.7. Two months later the patient presented with swelling and suppuration from alveolar socket of 4.7 interpreted as super-infection. Despite the antibiotic therapy (amoxicillin 1gr 2/die) lasting for >1 month, no

improvements were identified and the patient reported the occurrence of lower right lip dysesthesia. The patient was referred to our department where ONJ of unknown origin was suspected since the patient continued to neglect using drugs at risk for MR-ONJ. Medical history of the patient was verified again also with the aid of her primary care physician and finally we realized that S.M. was taking ibandronic acid since about 20 years as therapy for osteoporosis. SPECT-CT was employed for diagnostic and pre-operative evaluation of MRONJ. On August 2017 surgical intervention for MRONJ together with the extraction of 4.6 was performed in general anaesthesia. The patient was clinically and radiologically healed at 6 months follow-up evaluation.

**CONCLUSIONS:** Considering the prevalence of osteoporotic patients treated in our institution during 2017 (5 out of 12 surgical interventions for MR-ONJ in general anaesthesia) in two cases MR-ONJ was found to complicate tooth extraction performed without proper preventive measures because of unreported oBP consumption. Patients' lack of knowledge about their medicaments and their adverse effects could be another relevant factor in relation to MR-ONJ risk. Accurate information regarding oBP among patients should be enhanced and a recommendation for a dental preventive evaluation before beginning oBP could be advisable as well as improved cooperation between dentist and other physicians in assessing MR-ONJ risk of these patients. SPECT-CT often used for cancer's staging among oncologic patients<sup>1</sup>, was found to be an useful instrument in diagnosis and preoperative evaluation of MR-ONJ in this case.

#### REFERENCES:

1. Khan A.A. *et al.* Diagnosis and Management of Osteonecrosis of the Jaw: A Systematic Review and International Consensus JBMR, Vol. 30, No. 1, Jan 2015, 3–23
2. Linee guida intersocietarie sull'osteoporosi 2017 [http://www.siomms.it/wp-content/uploads/2017/06/Linee-Guida\\_OP\\_Intersocietarie.pdf](http://www.siomms.it/wp-content/uploads/2017/06/Linee-Guida_OP_Intersocietarie.pdf)
3. J.S. Bauer *et al.* Awareness and education of patients receiving bisphosphonates J. Craniomaxillofac Surg 40 (2012) 277e282

## FUORI QUOTA

### F01 - Treatment of bone metastases: bisphosphonates, denosumab and ongoing research

F. Pantano \*

UNICAMPUS, Rome, Italy

**BACKGROUND:** Bone metastases are associated with severe morbidity, pain and functional impairment. Adequate treatment may decrease morbidity, improve quality of life and (in some cases) improve survival. The medical treatment of bone metastases from most of primary cancers is mostly based on bisphosphonates (e.g. pamidronate, ibandronate, and zoledronic acid) and denosumab, but other drugs are active on bone. For example, abiraterone and enzalutamide act on bone microenvironment and delay bone progression. Radium 223 is able to improve overall survival, to improve quality of life, to delay SRE, to delay bone progression. Everolimus is able to reduce bone turnover marker levels and to delay bone progression. Current knowledge and ongoing research studies are examined.

### F02 - Multiple myeloma (MM): therapy on evolution

A. Baraldi \*

Hematology Unit, Azienda Ospedaliera "SS. Antonio e Biagio e C. Arrigo", Alessandria, Italy

**BACKGROUND:** The treatment of myeloma is based on specific drugs (chemotherapy, steroids, and targeted and biological therapy), together with agents acting specifically on bone turnover, i.e. bisphosphonates (BP), and denosumab. Bone marrow (stem cell) transplant is an option for selected patients. However, the treatment of newly diagnosed multiple myeloma has changed dramatically over the past 20 years, from the only chemotherapy to a patient-selected approach, based on age, performance status, frailty, comorbidities, and disease aggressiveness. The number of novel therapies is rapidly growing, due to clinical trials evaluating them in combination with other novel and established therapies. Proteasome inhibitors, immunomodulatory agents and monoclonal antibodies are studied classes of novel agents, with histone deacetylase inhibitors, nuclear export inhibitors and several other approaches also being actively investigated. On clinical practice, out of transplanted patients, therapeutic elements (e.g., first line drugs; maintenance strategies; consolidation; etc) have to be decided on an individualized appraisal of risk and toxicities. Inclusion of patients in study protocol whenever possible is to encourage. Denosumab has been recently shown at least as active as zoledronic acid on reducing and delaying Skeletal Related Events (SRE) in myeloma patients. .

#### REFERENCES:

1. Wallington-Beddoe CT, *et al.* Resistance to proteasome inhibitors and other targeted therapies in myeloma. Br J Haematol. 2018.
2. Willenbacher E, *et al.* Short overview on the current standard of treatment in newly diagnosed multiple myeloma. Memo. 2018.
3. Raje N, *et al.* Denosumab versus zoledronic acid in bone disease treatment of newly diagnosed multiple myeloma: an international, double-blind, double-dummy, randomised, controlled, phase 3 study. Lancet Oncol. 2018

### F03 - Osteoporosis treatment: present and future

M. Massara

SC Medicina Fisica e Riabilitazione, Azienda Ospedaliero-Universitaria "Ospedale Maggiore", Novara, Italy

The prevention and the treatment of osteoporosis may involve diet and nutrition, exercise, lifestyle change (to strengthen bone tissue and reduce the risk of fractures) and medications, including bisphosphonates (BPs), denosumab, teriparatide, raloxifene and other drugs, as well as calcium and Vitamin D. The most prescribed BPs are : oral alendronate (70 mg/week); oral risedronate (35 mg/week); iv ibandronate (3 mg q3months); oral ibandronate (150 mg monthly); yearly iv zoledronic acid (5 mg q12months). Denosumab (at the dose of 60 mg every six months) recently became a valid alternative to BPs due to advantages (subcutaneous injection; long effect) in spite of higher economic cost. In postmenopausal women, most of recommendations and guidelines underline importance of the treatment of women with severe fractures, in whom the use of drugs is recommended; zoledronic acid is preferred as the first-line drug after a hip fracture. In patients

with or without non-severe fractures, the decision to use osteoporosis medications is based on bone mineral density values and, in challenging cases, on probabilities supplied by prediction tools such as FRAX® or the Italian DEFRA. Raloxifene should be reserved for patients at low risk for peripheral fractures. The fracture risk should be reevaluated every 2 to 3 years to decide on the best follow-up treatment. About long-term strategies bisphosphonates are often considered first-line treatment for osteoporosis, but treatment duration is limited, based on potential long-term safety concerns, and there is no consensus about what to do after a certain number of years (i.e., five years of alendronate or three years of yearly zoledronic acid). There are no recommendations concerning long-term management of osteoporosis over 30 or more years of postmenopausal life.

**F04 - Osteonecrosis of the jaw (ONJ): pharmacovigilance in Piedmont and in Italy**

E. Marrazzo \*  
 ???????

Medication Related ONJ, or MRONJ, has been reported to Pharmacovigilance Authorities in patients treated with bisphosphonates (BP), denosumab, and other drugs. In Italy the national pharmacovigilance database is managed by the national health authority (AIFA). Notifications of side effects are theoretically mandatory but actually rare: the system is based on spontaneous reports from professionals. On April 2018, in Piemonte (North-Western Italy) only 77 ONJ cases were referred to the national Pharmacovigilance system (against more than 600 cases surveyed by Gambino, Fusco *et al.*). Such a data report will be compared with data from the whole national system and from other sources.

**F05 - ONJ update: etiopathogenetic hypotheses and animal models**

K. Rupel, M. Biasotto  
 Department of Medical, Surgical and Health Sciences, University of Trieste, Trieste, Italy

Comparative medicine has developed on the basis that other animal species share several physiological, behavioral, or other characteristics with humans and thanks to these techniques scientists employ animal models throughout biomedical research fields (1). Despite the fact that in recent years there is a growing consideration of ethics in animal experimentation and the use of animals is constantly reducing, animal models are fundamental to shed a light on unanswered pathophysiological issues, such as the etiopathogenesis of medication-related osteonecrosis of the jaws (MRONJ). Several hypotheses have been provided in the last decade: the oversuppression of bone remodeling, the inhibition of neoangiogenesis causing an ischemic necrosis resembling osteoradionecrosis, the possible central role of infection by oral bacteria, a possible toxic effect on keratinocytes and other soft tissue cell lines and a direct immunosuppressive effect (2). Recently, thanks to studies animal models of MRONJ, several novel aspects have been highlighted. Firstly, the central role of bone remodeling inhibition has been corroborated by a similar incidence of ONJ observed with other antiresorptive medications such as denosumab, both in humans and in animal models. In latter ones, several studies have highlighted

how the level of bone inhibition and the risk for ONJ onset are even higher in denosumab-treated mice (3). Subsequently and interestingly, in the last couple of years a pair of studies have performed more complex histomorphometric, micro-TC and Raman spectroscopy analysis on bisphosphonate-treated animal jawbones, and found in both cases an increase in bone density and corticalization, and a decrease in vascularization (4,5). This is of particular interest since the hypothesis of an ischemic component in ONJ onset had been previously rejected (6). Unfortunately, the etiopathogenetic mechanisms underlying MRONJ have not been fully explained yet even if it is undoubtable that the inhibition of osteoclasts plays a central role. A study involving animal models showed how bisphosphonates accumulate in sites of infection/trauma (7), and other studies highlight confirm that tooth extractions are more important triggers for MRONJ onset than mucosa wounds, especially if teeth had periradicular disease (8,9). A question that remains unanswered, which is one of the most crucial, is the reason for its localization at jawbones. For this reasons, it is fundamental to continue to design and perform studies involving animal models to improve efficacy of MRONJ patients' treatment and disease prevention.

REFERENCES

- Ericsson AC, Crim MJ, Franklin CL. A brief history of animal modeling. *Mo Med.* 2013 May-Jun; 110(3):201-5.
- Ruggiero SL, Dodson TB, Fantasia J, Goodday R, Aghaloo T, Mehrotra B, O’Ryan F; American Association of Oral and Maxillofacial Surgeons. American Association of Oral and Maxillofacial Surgeons position paper on medication-related osteonecrosis of the jaw--2014 update. *J Oral Maxillofac Surg.* 2014 Oct; 72(10):1938-56.
- Williams DW, Lee C, Kim T, Yagita H, Wu H, Park S, Yang P, Liu H, Shi S, Shin KH, Kang MK, Park NH, Kim RH. Impaired bone resorption and woven bone formation are associated with development of osteonecrosis of the jaw-like lesions by bisphosphonate and anti-receptor activator of NF-κB ligand antibody in mice. *Am J Pathol.* 2014 Nov; 184(11):3084-93.
- Kün-Darbois JD, Libouban H, Mabilieu G, Pascaretti-Grizon F, Chappard D. Bone mineralization and vascularization in bisphosphonate-related osteonecrosis of the jaw: an experimental study in the rat. *Clin Oral Investig.* 2018 Feb 16.
- Silveira Soares MQ, Van Dessel J, Jacobs R, Sérgio da Silva Santos P, Cestari TM, Garlet GP, Duarte MAH, Imada TSN, Lambrichts I, Rubira-Bullen IRF. Zoledronic Acid Induces Site-Specific Structural Changes and Decreases Vascular Area in the Alveolar Bone. *J Oral Maxillofac Surg.* 2018 Mar 15.
- Mitsimponas KT, Moebius P, Amann K., Stockmann P, Schlegel KA, Neukam FW, Wehrhan F. Osteo-radio-necrosis (ORN) and bisphosphonate-related osteonecrosis of the jaws (BRONJ): the histopathological differences under the clinical similarities. *Int J Clin Exp Pathol.* 2014 Jan 15; 7(2):496-508.
- Cheong S, Sun S, Kang B, Bezouglaia O, Elashoff D, McKenna CE, Aghaloo TL, Tetradis S. Bisphosphonate uptake in areas of tooth extraction or periapical disease. *J Oral Maxillofac Surg.* 2014 Dec; 72(12):2461-8.
- Zandi M, Dehghan A, Janbaz P, Malekzadeh H, Amini P. The starting point for bisphosphonate-related osteonecrosis of the jaw: Alveolar bone or oral mucosa? A randomized, controlled experimental study. *J Craniomaxillofac Surg.* 2017 Jan; 45(1):157-161.
- Soundia A, Hadaya D, Esfandi N, *et al.* Osteonecrosis

of the Jaws (ONJ) in Mice after Extraction of Teeth with Periradicular Disease. *Bone*. 2016;90:133-141. doi:10.1016/j.bone.2016.06.011.

### **F06 - Osteonecrosis of the jaw (ONJ) not related to bisphosphonates: topic issues from recent literature**

P.G. Arduino \*

*Oral Medicine Unit, Surgical Sciences Department, CIR-Dental School, University of Turin, Turin, Italy*

Bisphosphonates (BP) are widely used for treatment of hypocalcaemia associated with metastatic cancer and multiple myeloma, and also in Paget disease, imperfect osteogenesis, and osteoporosis. Although generally well tolerated, in some patients BP treatment could cause adverse events such as atrial fibrillation, acute phase response, and BP-related osteonecrosis of the jaw (BRONJ), the last have being reported since 2003. More recently, the terms MRONJ (medication related osteonecrosis of the jaw) and/or ARONJ (antiresorptive drug related osteonecrosis of the jaw) have replaced the term BRONJ, because other medications have been detailed to have the same adverse effects. By definition this disease reflects an area of exposed bone in the jaw persisting for more than 8 weeks with no history of radiation therapy while having undergone a bisphosphonate or other anti-resorptive drug therapy. To date, incidence of ARONJ/MRONJ has been reported to be between 0.01% - 0.04%, while, consequent to bisphosphonate administration, the incidence of BRONJ has been detailed of 0.8% up to 12%. Aim of this report was that of describe the current concept of recent topic in literature data about non-BRONJ manifestation, describing the more involved medication, the clinical feature and latest advance in treatment. A brief description of the cases observed at the CIR-Dental School, University of Turin, have been also performed, briefly reporting a percentage of less than 3% of the total cases of osteonecrosis in the last 10 years (4 cases of ARONJ/MRONJ vs. more than 160 of BRONJ). In conclusion, different medication can cause jaw osteonecrosis instead of BP (e.g. denosumab, bevacizumab, sunitinib, sorafenib, pazopanib, axitinib, everolimus and temsirolimus) even if with a low percentage (usually less than 6%); oral health care providers should be aware of this in order to prevent the possibility of these effects.

#### REFERENCES:

1. Fusco V, Santini D, Armento G, Tonini G, Campisi G. Osteonecrosis of jaw beyond antiresorptive (bone-targeted) agents: new horizons in oncology. *Expert Opin Drug Saf*. 2016 Jul;15(7):925-35.

### **F07 - Osteonecrosis of the jaw (ONJ): pharmacovigilance in piemonte and in Italy**

P. Carcieri, A. Gambino, M. Cabras, P. G. Arduino, S. Carossa  
*Department of Surgical Sciences, Oral Medicine Section, CIR Dental School, University of Turin, Turin, Italy*

To the best of our knowledge, there is no study that investigated the influence of oral health and hygiene on the healing process after surgical resection of MRONJ (medication related osteonecrosis), but some studies demonstrate the importance of a healthy dental and oral status and the performance of

parodontal treatment during BP treatment in order to delay the onset of MRONJ. The relationship between preventive treatment protocols and improvement of oral hygiene with a lower rate of MRONJ has been usually investigated, retrospectively: in 2013, Krimmel evaluated the time of occurrence of ONJ after treatment onset with bisphosphonates using Kaplan-Meier estimator and logrank test. In 2014 Krimmel highlighted the great benefit of good dental and oral health in the prevention of MRONJ: without parodontal treatment, MRONJ occurred 15 months earlier compared to patients undergoing parodontal treatment the question whether other underlying and pre-existent dental pathologies may predispose patients for the development of MRONJ is only partially addressed in the literature. However, dental hygienist can play a fundamental role in periodontal status of these patients and in the performance of parodontal treatment during bisphosphonates or other medications to delay the onset of MRONJ.

#### REFERENCES:

1. Krimmel M, Ripperger J, Hairass M, Hoefert S, Kluba S, Reinert S. Does dental and oral health influence the development and course of bisphosphonate-related osteonecrosis of the jaws (BRONJ)? *Oral Maxillofac Surg*. 2014 Jun;18(2):213-8

### **F08 - Reducing risk of osteonecrosis of the jaw (ONJ) and attitude of young oncologists worldwide: preliminary report of a brief online survey**

A. Addeo <sup>1</sup>, V. Fusco <sup>2</sup>, Alberto Bedogni <sup>3</sup>

<sup>1</sup>*Oncology Department, HUG – University Hospital of Geneva, Geneva, Switzerland;* <sup>2</sup>*Oncology Unit and ONJ Documentation Center, Alessandria Hospital, Alessandria, Italy;* <sup>3</sup>*Maxillofacial Surgery Unit and Regional Center for diagnosis and treatment of ONJ, Padua University Hospital, Padua, Italy*

**BACKGROUND:** Several published reports suggest a relationship between the use of antiresorptive agents (bisphosphonates, denosumab) and the development of osteonecrosis of the jaw (ONJ) in bone metastatic cancer and myeloma patients. International guidelines have been designed to manage properly the risk of ONJ but disparities seemingly occur in the daily clinical routine. The adherence to these guidelines across the world is rarely reported and likely to be scarce. We present the preliminary results of a survey posted to oncologists from different countries with the aim of getting a clearer picture of routine management of ONJ patients worldwide.

**METHODS:** An anonymous online survey including 4 questions regarding the management of ONJ was launched through several social networks and sent to cancer specialists. Gender, age and working countries of the participants were also collected.

**RESULTS:** Of the initial 64 responders, 37 were male (57%) and 27 female (43%); the median age (range) was 37 years. (range 28-57). The main working countries were: UK (20 =31%), Italy (14=21%), Switzerland (12=19%), USA (3=4,5%). Other responders were from Germany, Spain, Portugal, Poland, Macedonia Rep, Romania, Georgia, Algeria, Qatar, Vietnam, Pakistan, India, Egypt.

Questions and answers were the following:

1. Before prescription of antiresorptive drugs (zoledronic acid, denosumab, etc) in bone metastatic and myeloma patients, you require a careful dental evaluation:
  - a) Always, systematically 37 (57,81%)
  - b) Most of cases 15 (23,44%)

c) Only in case of bad oral hygiene or dental disease 8 (12,50%)

d) Rarely, seldom 4 (6,25%)

e) Never 0

2. The usual dental evaluation before beginning the antiresorptive treatment is:

a) Rx OPT and dental visit 32 (50%)

b) Rx OPT only 2 (3,13%)

c) Dental visit alone 27 (42,29%)

d) None 3(4,69%)

3. In case a tooth extraction is recommended by dentist before the beginning of antiresorptive treatment:

a) You usually begin the treatment immediately, delaying the tooth extraction 4 (6,25%)

b) You delay the antiresorptive treatment till to extraction and socket healing 44 (68,75%)

c) You immediately begin the treatment in selected unfavorable cases (ie "aggressive" bone metastatic disease), and delay the treatment in most of cases 15 (23,44%)

d) You begin the treatment in most of cases, and delay the treatment only in favorable selected cases (ie, asymptomatic disease, good prognosis disease) 1 (1,56%)

4. After tooth\teeth extraction, you usually begin the antiresorptive treatment :

a) After 2 weeks, following dental control visit (if healed socket) 14 (21.88%)

b) After 4 weeks, following dental control visit (if healed socket) 37 (57,81%)

c) After 4 weeks, independently by dental control visit 3 (4,69%)

d) After 6-8 weeks, independently by dental control visit 8 (12,5%)

e) Other 2 (3,13%)

**CONCLUSIONS:** Preliminary results of the survey show a high degree of adherence to International recommendations in order to reduce the ONJ risk before initiation of an antiresorptive treatment in bone metastatic and myeloma patients. The attitude to delay the start of therapy until complete healing in case of required dental extraction is more heterogeneous. Additional responders are awaited to perform statistical analyses and display the results by geographic areas.

### **F09 - Osteonecrosis of jaw (ONJ) consensus: work in progress in europe**

A. Bedogni \*

*University of Padua, Padua, Italy*

An European work group was established to analyze medical literature and to evaluate a possible ONJ definition and, if it is possible, a new staging system. The first meeting was held in Copenhagen on September 2017. The group encases seven European experts on MRONJ, who are highly recognized clinicians and scientists from Germany, Italy, England, Greece, Switzerland and Denmark with notable track records of research and scientific publications in the field. Based on the most recent evidence, these experts are trying to provide an update for dentists, clinicians, OMF Surgeons and other specialists on classification, clinical manifestations, treatment, pathogenesis and prevention of MRONJ. The work is aimed at dentists, maxillofacial surgeons, oral medicine physicians, other specialists and all clinicians who have an interest or manage patients with MRONJ.

### **F10 - Osteonecrosis of the jaw (ONJ): pharmacovigilance in france and challenge for incidence estimation**

P. de Boissieu \*

*Epidemiology and Public Health Department, Kremlin-Bicetre University Hospital, Paris University Hospitals (APHP), Hôpitaux Universitaires Paris-Sud, Paris, France*

**BACKGROUND:** Medication Related ONJ, or MRONJ is mostly linked to bisphosphonates (BP), denosumab, and other drugs. Benefit risk assessment of drugs is based on Randomized Clinical Trial reports (study data) and on post-marketing data (real life), with pros and cons. In France the national pharmacovigilance database is managed by the national health authority; notifications of side effects are mandatory but actually the system is based on spontaneous reports from professionals and patients. The quality process is assured by regional pharmacovigilance centers (analysis, request for further information) and scientific and medical "validation" of the data. Limits of the system include: under-reporting; not uniform temporal trends in reporting; insufficient quality of reports. At 2014, the French pharmacovigilance database included only 630 cases of BRONJ, with under-estimation of incidence. Specific studies (as those conducted in Scandinavian countries) are needed to estimate ONJ incidence after drug initiation, but limits are linked to the extension (national) and the costs. On the other hand, clinical database with medical records are specific for each hospital or health professional and not easy to be linked one another. In France one possible source of data might be the insurance health system reimbursement database, that is national and mandatory, covering 95% of the French population. It is perfect to register starting of treatment with involved drugs (BPs, denosumab) linked to medical information based on ICD-10 codes (M87.1 and K10.2) for hospitalized patients. Strengths of that possible source: large sample size (all French population); accurate records for reimbursed drugs (exposure); national (public and private hospitals). Limits of this source are multiple. Firstly, it is designed for reimbursement, not for research. Secondly, a research algorithm based on ICD-10 codes needs to be validated. Furthermore, it is limited to hospitalization (missing ONJ cases not hospitalized). Finally there are possible unmeasured confounding factors (eg, radiotherapy). In conclusion, ONJ incidence in France needs to be investigated; French pharmacovigilance system is too biased; the French National System for health data could be useful, but several issues need to be addressed (algorithm validation; unmeasured confounding).

### **F11 - Medical treatment of MR-ONJ: getting out of the box**

A. Marciano<sup>1</sup>, G. Oteri<sup>2</sup>

*Department of Biomedical and Dental Sciences and Morphofunctional Imaging, University of Messina, University Hospital "Gaetano Martino", Messina, Italy*

In 2014 the AAOMS updated its considerations about medication-related osteonecrosis of the jaws (MR-ONJ), considering as treatment goal for those patients the maintenance and improvement of the oral health related quality of life (QoL). In other words the goal of MR-ONJ treatment (non-surgical and surgical) is symptomatic relief rather than complete healing and the prevention of its significant morbidity which may lead to compromising patient's well being up to necessary cancer therapy suspension. The impact of exposed bone super-infection on the severity of



MR-ONJ has been evaluated and therefore the potential treatment strategies. According to the Italian Society of Oral Medicine and Pathology (SIPMO) approach the presence/absence of suppuration is a fundamental feature for correct staging of the disease. Therefore conventionally when we refer to medical treatment we mean a wide range of antibiotics in combination with antiseptic mouth rinses administered with different dosage and schedule until either full recovery or substantial improvement is reached or as a complement to surgical treatment. Non-surgical treatment options entail the use of antimicrobials such as chlorhexidine 0.12% or 2% rinse and antibiotics. Common antibiotics employed include amoxicillin, amoxicillin with clavulanic acid, clindamycin and/or metronidazole, other non surgical treatments are hyperbaric oxygen (HBO), medical ozonotherapy (MOT) and low-level laser therapy (LLLT); nevertheless even if stage-specific therapy has reached general agreement, clear treatment guidelines are not available for the non surgical approach by specifying what medications should be preferred and the optimal duration of pharmacological therapy.

On the side of the much debated role of targeted vs empiric antibiotic therapy new pharmacological treatments have appeared. The research is focusing on testing the efficacy of innovative molecules in reversing the effect of anti-resorptive and anti-angiogenic drugs in order to identify a novel pharmacological approach to MR-ONJ medical treatment. Teriparatide as an osteoanabolic agent has shown encouraging results in MRONJ osteoporotic patients. More recently the efficacy and safety of pentoxifylline and tocopherol (PENT-E) in the management of MR-ONJ has been demonstrated, also suggesting the use of PENT-E prophylactically in patients at increased risk with concomitant oral diseases for osteoradionecrosis. Furthermore the hypothesis that systemic or local treatment with anti-angiogenic inhibitors could lead to new therapeutic strategies for MR-ONJ has been investigated bringing to the attention agents such as geranylgeraniol (GGOH). Our mission as health providers is to reach positive results in improving quality of life of our patients leading to the research of safe effective and efficient care solutions. In the light of these considerations we are committed to investigate on novel medical biotechnologies for treatment of MR-ONJ disease, getting out of the box, identifying among emerging agents the best option for non surgical MR-ONJ treatment, reiterating the need for an individualized treatment plan with the aim to reduce skeletal related adverse effects and improve quality of life.

## **F12 - Surgical treatment of medication-related osteonecrosis of the jaws: UPDATE 2018**

G. Oteri, A. Marciano<sup>1</sup>

*Department of Biomedical and Dental Sciences and Morphofunctional Imaging, University of Messina, University Hospital "Gaetano Martino", Messina, Italy*

**BACKGROUND:** The more recent position papers on medication-related osteonecrosis of the jaws (MR-ONJ) have been issued by American Association of Oral and Maxillofacial Surgeons in 2014 and by Japanese Allied Committee on Osteonecrosis of the Jaws in 2017; nevertheless to date no official guidelines are available for the management of patients with MR-ONJ; the existing management directions

are mostly the result of the experience of specialized centers and even if stage-specific therapy has reached general agreement, precise treatment guidelines for the surgical approach have not been drawn. Interventions range from conservative debridement to major resection, often without a precise definition or description of the extent of bone removal. The ideal would be to reach a consensus, defining case features and details of the required intervention (e.g., debridement, conservative resection, or segmental resection).

**METHODS:** A narrative review of the last four years literature on the topic of surgical treatment of medication-related osteonecrosis was performed.

**RESULTS:** In the indicated period about eighty studies were published. Several of them were excluded after a careful reading of the abstract. The identified studies mainly focused on bisphosphonates rather than on denosumab or other oncologic drugs (Pichardo 2016, Hoefert 2017). Analyzing in brief the noteworthy aspects, most of the studies were retrospective analyzes (Hoefert 2017, Kim 2017, Hayashida 2017, Eguchi 2017, Zirk 2017, Voss 2016, Nisi 2016, Pichardo 2016). In most cases the patient cohort was limited and some were case series (Pichardo 2016). The majority of prospective studies aimed to investigate the use of healing promoters such as bone marrow mesenchymal stem cells (MSCs) (Voss 2017), bovine lactoferrin (Calvani 2018), leukocyte (Maluf 2018), platelet-rich plasma (PRP) (Fornaini 2017) and platelet-rich fibrin (PRF) (Maluf 2018, Inchingolo 2017, Park 2017, Nørholt 2016). Other studies reported advanced surgical techniques such as repositioning flaps (Lemound 2018). Systematic reviews did not include randomized clinical trials or case and control studies (Ramaglia 2017) therefore the collected data are not enough to draw definite conclusions.

Moreover other reviews, although published recently, were referred to papers published before 2014 (Silva 2016). In the considered studies cancer and osteoporotic patients were often included in the same analyzed cohorts. The issues of peri-operative antibiotic therapy and drug holiday were poorly addressed. All stages have been considered but except for Kim (2017) and Zirk (2017) studies did not include a comparison between the different possible surgical techniques. In general, the surgical outcome was evaluated in terms of clinical wound healing without dehiscence or evidence of recurrence (Blus 2017, Bodem 2016, Klingelhöffer 2016). Only few studies addressed the symptomatology related to MR-ONJ (Blus 2017) or the impact of treatment on patient's quality of life (Oteri 2018).

**CONCLUSIONS.** Considerations deriving from this revision underline the approach oriented towards surgical treatment in all MR-ONJ stages and the need to conduct larger clinical studies in terms of number of patients and follow-up periods, to provide clear indications about surgical treatment of MR-ONJ and its prognostic parameters.

## **F13 - MRONJ: evolution of the disease and the evolution of its surgical treatment**

G. Ramieri, P. Garzino-Demo, F. Rocchia

*Division of Maxillofacial Surgery, Surgical Science Department, University of Torino, Turin, Italy*

Not only the bisphosphonates (BRONJ) and the denosumab (DRONJ) but also antiangiogenic drugs (bevacizumab, sunitinib, sorafenib, cabozantinib), are associated to the osteo-

necrosis of the jaws (MRONJ). Recently other targeted therapies drugs (axitinib, pazopanib, aflibercept, ipilimumab) were reported as causal factors. This list is not exhaustive and a new series of biological drugs will continue to enrich it. There are no guidelines final and commonly accepted on therapy of MRONJ. They are often adopted individual protocols. The current strategy is that the therapeutic treatments must be in line at the stage of the disease<sup>2</sup>. Some hinges of treatment remain the subject of debate: (1) what is the treatment for the stage with the best results, (2) when they should be the period of “drug holiday” ideal and (3) that type of antibiotic therapy to put in the act. The medical therapy has a percentage of success, which decreases with the increase of the stage, while the surgical therapy has a success percentage decidedly heterogeneous for the stage. The lines of treatment of MRONJ in stage 1 and stage 3 lesions are generally well defined. A targeted review of the effectiveness of surgical vs medical therapy for stage 2 lesions would be extremely relevant. As regards the “drug holiday” although the statistical analyzes show an increase in the prevalence of healings when it is implemented, from the medical point of view may be suggested that this protocol shall not be adopted for the presence of necrosis, but according to the state of health of each patient. Radical surgical treatment, at stage 3<sup>3</sup>, has to be considered when (1) MRONJ seems to involve a large area of the jaw, (2) the disease is not resolved by conservative approach, (3) the donor site is well perfused, and (4) the preoperative exclusion of bone metastases at the donor site is performed. At the authors’ institution, the patient is the main driver behind the decision to perform a radical surgical treatment. These patients are often in pain and highly motivated to proceed with resection. Most are treated with conservative therapy as advocated; however, some patients are no longer able to experience a good quality of life and are considered candidates for surgical resection and immediate reconstruction.

## REFERENCES:

1. Jung T-Y. Osteonecrosis of jaw after antiangiogenic agent administration in a renal cell carcinoma patient. *Oral Maxillofac Surg Cases*. 2017;3:27-33.
2. Ramaglia L, Guida A, Iorio-Siciliano V, Cuozzo A, Blasi A, Sculean A. Stage-specific therapeutic strategies of medication-related osteonecrosis of the jaws: a systematic review and meta-analysis of the drug suspension protocol. *Clinical Oral Investigations* (2018) 22:597–615
3. Ghazali N, Dyalram D, Lubek JE. Surgical resection and vascularized bone reconstruction in advanced stage medication-related osteonecrosis of the jaw. *Int J Oral Maxillofac Surg*. 2017 Jul;46(7):871-876.

### F14 - Low level laser therapy and osteonecrosis

M. Meleti \*

*University of Parma, Parma, Italy*

Tissue biomodulation through low level laser therapy (LLLT) has gained interest with regard to the management of medication-related osteonecrosis of the jaws (MRONJ) or its prevention. About 30 relevant papers (including a systematic review) have been published in the last 5 years on such topics. According to the recent relevant literature, it would seem that LLLT (alone or in combination with other therapies) could be of some benefit for patients with MRONJ. Particularly, biomodulation can promote a faster healing of soft and hard tissue, can reduce pain and can decrease signs of infection.

Some Authors have reported an influence of LLLT on necrotic bone sequestra elimination. Biomodulation after surgical treatment (e.g. post-extractive) in patients administered with medications potentially related to osteonecrosis of the jaws seem to be effective in reducing the occurrence of such a problematic side effect.

### F15 - Ultrasonic piezoelectric bone surgery for ONJ treatment: a systematic review of literature

R. Mauceri <sup>1,2\*</sup>

<sup>1</sup>*Dept. of Surgical, Oncological and Oral Sciences, University of Palermo, Palermo, Italy;* <sup>2</sup>*Oral Medicine and Dentistry for Patients with Special Needs, Department of Sensorineural and Motor Surgery, AUOP “P. Giaccone” of Palermo, Palermo, Italy*

**BACKGROUND:** Main goals of the Osteonecrosis of the jaw (ONJ) treatments is to reduce pain, to control infection and to slow the progression of the disease or, when it is achievable, to have a complete healing, eradicating the necrotic bone and, so, the infection<sup>1,2</sup>. However, the ONJ management is still controversial and there are no evidence-based guidelines on the management of this disorder. Piezoelectric surgery, also known as ultrasonic bone surgery, has been introduced more the fifteen years ago; and it has been widely applied in oral and maxillofacial surgery, replacing conventional rotary systems and oscillating saws<sup>3,4</sup>. The advantages of its use are a greater cutting precision combined with the possibility to maintain along the cut an area of vital and highly reactive bone. Furthermore, it seems to enhance the hard tissue healing process and to possess a bactericide effect related to the cavitation effect produced during the cutting procedures<sup>4–6</sup>. This systematic review aimed to evaluate if the application of a piezoelectric device may improve the surgical treatment of ONJ

**METHODS:** An electronic search was performed on the following databases: MEDLINE, Web of Science and Cochrane. The following search terms were used: “treatment” “ONJ”, “BRONJ”, “MRONJ”, “DRONJ”, “osteonecrosis”, “ultrasonic bone surgery”, “piezoelectric surgery”, “piezosurgery”. The search was limited to clinical studies involving human subjects published between 2014 and 2018. Restrictions were not placed regarding the language as well as to the design of the study and the sample size. The studies had to provide details on the type of ONJ-related medication taken, the indication for the therapy and the duration of the treatment at the time of surgery. They also had to provide clear the application of ultrasonic device for the ONJ treatment and the definitions of the clinical outcomes for considering success or failure of the procedure.

**RESULTS:** Only one study was included, reporting on 20 treated sites. The ultrasonic device was applied to perform curettage, debridement, sequestrectomy, corticotomy, osteoplasty, and marginal bone section. Post-surgery follow-up ranged from 10 months up to 54 months. Healing was obtained in all patients included in the study<sup>7</sup>.

**CONCLUSIONS:** There is a lack of evidence regarding the application of piezoelectric device for the ONJ treatment and it is usefulness. Although the results of Blus *et al.* are positive<sup>7</sup>; to confirm such indication, prospective comparative studies with a large sample size are necessary.

## REFERENCES:

1. Beth-Tasdogan NH, Mayer B, Hussein H, Zolk O. Interventions for managing medication-related osteonecrosis of the jaw. *Cochrane Database Syst Rev*. 2017;10:CD012432. doi:10.1002/14651858.CD012432.pub2.

2. Campisi G, Fedele S, Fusco V, Pizzo G, Di Fede O, Bedogni A. Epidemiology, clinical manifestations, risk reduction and treatment strategies of jaw osteonecrosis in cancer patients exposed to antiresorptive agents. *Futur Oncol.* 2014;10(2):257-275. doi:10.2217/fon.13.211.
3. Vercellotti T. Technological characteristics and clinical indications of piezoelectric bone surgery. *Minerva Stomatol.* 2004;53(5):207-214. <http://www.ncbi.nlm.nih.gov/pubmed/15263877>. Accessed April 15, 2018.
4. Pereira CCS, Gealh WC, Meorin-Nogueira L, Garcia-Júnior IR, Okamoto R. Piezosurgery Applied to Implant Dentistry: Clinical and Biological Aspects. *J Oral Implantol.* 2014;40(S1):401-408. doi:10.1563/AAID-JOI-D-11-00196.
5. Vercellotti T, Nevins ML, Kim DM, *et al.* Osseous response following restorative therapy with piezosurgery. *Int J Periodontics Restorative Dent.* 2005;25(6):543-549. <http://www.ncbi.nlm.nih.gov/pubmed/16353529>. Accessed April 15, 2018.
6. Thomas M, Akula U, Ealla KR, Gajjada N. Piezosurgery: A boon for modern periodontics. *J Int Soc Prev Community Dent.* 2017;7(1):1. doi:10.4103/2231-0762.200709.
7. Blus C, Giannelli G, Szmulker-Moncler S, Orru G. Treatment of medication-related osteonecrosis of the jaws (MRONJ) with ultrasonic piezoelectric bone surgery. A case series of 20 treated sites. *Oral Maxillofac Surg.* 2017;21(1):41-48. doi:10.1007/s10006-016-0597-7.

## F16 - Autologous blood concentrates in prevention and treatment of osteonecrosis of the jaw

C. Mortellaro \*

*Università del Piemonte Orientale, Novara, Italy*

Osteonecrosis of the jaw therapy-related (MRONJ) is a drug-related adverse event consisting of progressive bone destruction in the maxillofacial region of patients undergoing current or previous treatment with bisphosphonates or other drugs. Autologous platelet concentrates (APCs) have been shown to improve bone and soft tissue healing in oral surgery procedures. Our systematic review aims to assess whether APC can improve the treatment and prevention of MRONJ in patients receiving antiresorptive therapy. We performed an electronic search on the following databases: MEDLINE, Scopus, Web of Science and Cochrane. The following search terms were used: "bisphosphonates", "denosumab", "antiresorptive agents", "antiresorptive therapy", "BRONJ", "MRONJ", "osteoporosis", "osteonecrosis", "jaw", "mandible", "platelet rich plasma", "platelet concentrates", "platelet growth factors", "platelet rich fibrin", "PRP", "PRGF", "PRF", "Platelet-derived growth factor", "PDGF", "CGF", "Oral surgery", "tooth extraction", "the limit", "human beings" has been applied. To be included, the studies had to report the clinical results of oral surgery procedures in patients undergoing antiresorptive therapy. The articles reporting the treatment of an existing MRONJ condition and those reporting on the incidence / onset of MRONJ in patients were considered, subjected to oral surgery procedures. No language restrictions were imposed but the field was restricted to the last 4 years of publication : 2014-2018. Prospective and retrospective studies were included with at least 5 patients and 3-month follow-up. Case study / reports were not included. The studies had to provide details on the type and dosage of the antiresorptive drug and the indication for antiresorptive therapy. The publications that do not deal with original clinical cases (for example reviews, technical reports, expert opinions) have also been excluded. The

main variables extracted from each included study were: study design, study setting (university, hospital, private study), sample size, gender and age of patients, proportion of smokers, type, dosage and route of administration of the antiresorptive drug, reason for antiresorptive treatment, dosage, duration of surgical treatment, type of APC used, maxilla (maxilla or mandible), any outcome variable used to evaluate treatment success, duration of follow-up, complications, adverse events, post-surgical onset / recurrence of MRONJ.

**CONCLUSIONS:** Although the results of this review should be interpreted with caution, due to the low level of evidence of the included studies and the limited sample size, they suggest possible benefits of APC when associated with surgical procedures for the treatment or prevention of BRONJ. To confirm this indication, prospective comparative studies with a large sample size are urgently needed.

## F17 - Ozone therapy of osteonecrosis of the jaw (ONJ)

C. Del Gaizo \*

*Sector of Oral Medicine, University of Palermo, Palermo, Italy*

Osteonecrosis of the jaw (ONJ) is a severe adverse event related to several drugs with antiresorptive and/or antiangiogenic activity; it is a potentially painful and debilitating condition that can considerably affect the quality of life of patients. Treatment of ONJ is still a challenge and, lately, conservative surgical treatments are increasingly performed at all stages of the disease. Healing of ONJ may be stimulated by different optional treatments; the oxygen-ozone therapy (OT) is one of the most interesting with its antimicrobial and regenerative properties (1). Antimicrobial effect of OT is based on its strong oxidation effect with the formation of free radicals, as well as its direct destruction of almost all microorganisms. It has a therapeutic effect that facilitates wound healing and cell proliferation and improves the supply of blood (Akdeniz SS *et al.* 2018). Furthermore, OT may stimulate cell proliferation and soft tissue healing reducing pain, with an amelioration of QoL (2), particularly in cancer patients. In the international literature, different studies report that there is a significant improvement in wound closure with ozone therapy. Results consistently favor the application of ozone as a treatment for chronic wounds. Compared with standard care, ozone therapy as an advanced wound care treatment may improve the proportion of chronic wounds healed in a shorter amount of time, but further research is required (Fitzpatrick E *et al.* 2018). Recently, positive impacts of ozone plasma application on avascular bone necrosis were reported: (i) stimulating endogenous antioxidant system with active in free radical synthesis; (ii) activating blood circulation, increasing red blood cells and hemoglobin concentration, enhancing diapedesis and phagocytosis during inflammatory response; and (iii) stimulating all biologic reactions, and in particular tissue oxygenation processes, calcium, phosphorus, and iron metabolism, and having a well-known antimicrobial action. These mechanisms can be efficiently positive on alveolar bone and/or neighboring soft tissue (4). In our experience, OT by insufflation/injection has been carried out for prevention and treatment of ONJ related to AA and/or AR. The innovative procedure may ameliorate wound, accelerating mucosal healing and potentially reducing the risk of post-operative complications. The aim of this review is to analyze efficacy and safety of ozone as adjuvant therapy for prevention and management of ONJ-related to antiresorptive (AR) and antiangiogenic (AA) agents.

REFERENCES:

1. Rollason V, *et al.* Interventions for treating bisphosphonate-related osteonecrosis of the jaw (BRONJ). *Cochrane Database Syst Rev.* 2016 Feb 26;2:CD008455. doi:10.1002/14651858.
2. Vescovi P, *et al.* Conservative surgical management of stage I bisphosphonate-related osteonecrosis of the jaw. *Int J Dent.* 2014;2014:107690. doi: 10.1155/2014/107690
3. Fitzpatrick E, Holland OJ, Vanderlelie JJ. Ozone therapy for the treatment of chronic wounds: A systematic review. *Int Wound J.* 2018 Mar 13. doi: 10.1111/iwj.12907.
4. Akdeniz SS, Beyler E, Korkmaz Y, Yurtcu E, Ates U, Araz K, Sahin FI, Torun OY. The effects of ozone application on genotoxic damage and wound healing in bisphosphonate-applied human gingival fibroblast cells. *Clin Oral Investig.* 2018 Mar;22(2):867-873. doi: 10.1007/s00784-017-2163

**F18 - Pain management in osteonecrosis of jaw (ONJ): an orphan issue?**

F. Cassini, V. Fusco, M. Vincenti, G. Campisi, A. Bedogni  
 ???????????

Pain is certainly the symptom most affecting the patient affected by ONJ, when present. The pain is often of high intensity, even at night, and comes to significantly limit the patient's relationship life. Nevertheless, in a large number of patients pain does not appear to be present at the onset of the disease. Pain, on the nature of which various hypotheses have been advanced (i.e. neuropathic, infectious, inflammatory, myogenic pain), can appear in several types: i) odontalgia, not otherwise explicable in absence of a concomitant dento-periodontal pathology; ii) "bony" pain of a gravitational type, well limited to the ONJ site (more frequent to the mandible body); iii) pain radiated to the masticator and cervical muscles, which may recall the temporomandibular joint disorder (myogenic pain); iiiii) sinusitis pain; iiiiii) hyperesthesia or trigeminal pain (which selectively affects the branch at the ONJ onset). Pain symptom treatment is a critical part of ONJ therapy. However, literature about specific ONJ-related pain is scarce. Even if pain is often present in patients with disseminated neoplasms, who already use opioid drugs for the management of metastatic skeletal pain, often it is reported no direct benefit on the pain symptoms associated with ONJ. Furthermore, since pain is a subjective symptom that often influences the choice of treatments, given the need to monitor the evolution of pain over time in the face of the different therapies implemented, its measurement should be carried out by the use of a visual analogue scale (Visual Analogue Scale-VAS) or other tools, to be submitted to the patient at the first visit and at each subsequent follow-up visit, in order to monitor the progress of the disease and the effectiveness of treatments (1,2,3). Pain is never decisive for the ONJ diagnosis, although it represents an aggravating factor in the prognosis of the disease, because it is often poorly controlled and in some cases refractory to medical therapy. Finally, since there is no evidence that the presence or the appearance of pain in a patient affected by ONJ is associated with an advanced disease, it is questioned the pain as a stage discriminating factor (as in the AAOMS staging system) and it should be appropriate to use the pain symptom to distinguish different clinical conditions in a same stage (as in the SICMF-SIPMO

staging system). We performed a systematic review of ONJ literature with keyword and MESH terms referred to pain and its treatment, on PubMed and other literature sources on 2014-2018 years. Out of 2957 publications citing ONJ and published in the period, 350 papers reported about pain anyhow. Actually most of publications were case reports, or case series, or review, or about treatment and results. Only three papers has pain as object of study.

REFERENCES:

1. Saia G *et al.* Occurrence of bisphosphonate-related osteonecrosis of the jaw after surgical tooth extraction. *J Oral Maxillofac Surg.* 2010
2. Bedogni A, *et al.* Long-term outcomes of surgical resection of the jaws in cancer patients with bisphosphonate-related osteonecrosis. *Oral Oncol.* 2011
3. Miksad RA, *et al.* Quality of life implications of bisphosphonate-associated osteonecrosis of the jaw. *Oncologist.* 2011

**F19 - New technologies help the functional reconstruction in advanced-stage mandibular medication-related osteonecrosis of the jaw (MRONJ)**

A. Bedogni <sup>1</sup>, G. Bettini <sup>1</sup>, A. Sandi <sup>2</sup>, N. Abbasi <sup>1</sup>, G. Saia <sup>1</sup>

<sup>1</sup>Regional Center for Prevention, Diagnosis and Treatment of Medication and Radiation-related Bone Diseases of the Head and Neck University and Hospital Trust of Padua, Padua, Italy; <sup>2</sup>Sintac s.r.l., Biomedical Engineering, Trento, Italy

**BACKGROUND:** We aim to present the results of the use of patient-specific mandibular prosthesis to reconstruct advanced-stage mandibular medication-related osteonecrosis of the jaw (MRONJ). We retrospectively assessed a subpopulation of MRONJ patients who had their mandible reconstructed with patient-specific titanium replicas from a prospective cohort of patients operated at the Units of Maxillo-facial Surgery of Verona and Padua's Universities (Italy) between March 2012 and February 2018.

**METHODS:** Preoperative Computed tomography (CT) was used to assess the stage of disease (SICMF-SIPMO 2012) and the margins of bone resection. A virtual 3-D template simulated on CT scans was used to resemble the natural shape of patient's jaw and to design a mandibular prosthesis containing holes to fix the screws, together with customized cutting guides to improve bone resection and prosthesis fitting. We recorded surgical duration, type and severity of postoperative complications, hospitalization, and oral feeding after surgery. Further we followed up patients at three-month intervals. We wanted to assess the prosthesis suitability and its long-term functional result. Local ethical committee approved the study. **RESULTS:** Between March 2012 and February 2018, a total of 20 consecutive patients underwent mandibular reconstruction with patient-specific prosthesis: 10 were affected by MRONJ and enrolled in this study. They were mostly females (70%) with a mean age of 69 years (range 59-78yrs). Breast cancer was the most common diagnosis and zoledronate the most used antiresorptive. Five patients have had previous unsuccessful surgical treatment of MRONJ. Most patients were in the stage III disease at the time of surgery (60%). Cardiovascular disease was the most common finding. All patients were scored ASA 3 (Physical status classification system). We treated eight hemimandibular bone defects (LC

defect sec. Jewer DD *et al.* 1989), five of which had simultaneous replacement of the condylar unit (HL defect), and also two subtotal mandibular defects with one-sided condyle reconstruction (HLC defect) in one case. Temporary tracheostomy was used for postoperative breathing support in one patient only. Mean Duration of surgery was 270 min (range: 141-375). Oral feeding in most cases was resumed one day postoperatively (mean: 1.4 days; range 1-3). The patient with temporary tracheostomy died four days after surgery because of acute respiratory distress. Postoperative mucosal wound dehiscence occurred in two cases and required additional surgery. One patient developed severe facial swelling that was treated with medical therapy and hyperbaric oxygen therapy. Mean hospital stay was 12 days (range 4-44). Nine patients were available to follow up. Dental occlusion maintained stable over time. Few weeks after surgery, two prostheses extruded because of submental skin burn in one case and mucosal laceration in another, which had to be removed. Late skin extrusion of the prosthesis occurred in one patient (26-month follow-up) that required coverage with a free-flap. Two patients died of cancer-related disease at 18 and 38-month follow-up respectively. We did not detect any radiological signs of prosthesis' dislocation/fracture at a mean follow-up of 26 months (range 3-50).

**CONCLUSIONS:** Patient-specific mandibular prosthesis is a safe reconstructive option in advanced-stage mandibular MRONJ. Medically compromised patients can benefit from this technology, with reduced operative time and similar functional results as compared with microsurgical bone reconstruction. Further studies are needed to assess its long-term safety and advance prosthesis design.

**References:**

1. Bedogni A, Campisi G, Fusco V, Agrillo A. Raccomandazioni clinico-terapeutiche su osteonecrosi delle ossa mascellari associata a bisfosfonati e sua prevenzione. 2013. Cleup sc, Padova.
2. Bedogni A, Bettini G, Ferronato G, Fusetti S, Saia G. Replacement of fractured reconstruction plate with customized mandible implant: a novel technique. *Laryngoscope*. 2014 Feb;124(2):401-4.

## **F20 - Documentation center for osteonecrosis of jaw (ONJ) in Alessandria (Italy): a ten-year experience**

I. De Martino, M. Alessio, V. Fusco, D. Tartara, O. Bertetto  
*"Centro Documentazione Osteonecrosi" and Oncology Unit, Azienda Ospedaliera "SS. Antonio e Biagio e C. Arrigo", Alessandria, Italy; "Rete Oncologica Piemonte e Valle d'Aosta", Turin, Italy*

**BACKGROUND:** The ONJ, or MRONJ (medication-Related ONJ) is a disease of relatively recent acknowledgment (since 2003), reported in association with use of bisphosphonates (BP), denosumab, and other drugs in Oncology and Hematology patients, but also in other non-cancer patients (ie, osteoporosis and Rheumatoid Arthritis). Screening, diagnosis, primary and secondary prevention (risk reduction) of ONJ are very complex and somewhat controversial. At the Alessandria Hospital (North-Western Italy), an ONJ Multidisciplinary Team was established on autumn 2005, after first ONJ cases (breast and prostate cancer and myeloma patients) were observed. The ONJ Multidisciplinary Team include maxillofacial surgeons / den-

tists, oncologists, hematologists, nurses, radiologists, nuclear medicine and infective disease specialists, data managers.

**AIM:** To diffuse acknowledgment and awareness of ONJ epidemiology, risk factors, diagnosis tools, treatment, preventive measures.

**METHODS:** On 2008 the Alessandria ONJ Multidisciplinary Team launched the idea of a Documentation Centre about Osteonecrosis of the Jaw (Centro Documentazione Osteonecrosi) whose activity was planned to be useful to both professionals and patients. The activities of the Centre included collaboration with doctors and health professionals working in whole Italy to extend a common diagnostic pathway and a prevention strategy of ONJ. One important activity of the Centre is the collection and classification of all published issues on the topic (since 2003), both retrieved from scientific journals, and from other sources (ie, internet). Other data are collected by contacts with experts, research centres and health professionals dealing with the issue, in order to create a complete and detailed archive (updated monthly). Documents are sent, upon request, to healthcare professionals all over Italy

**RESULTS:** The Centre collected more than 3500 documents: medical literature publications (most of them as full papers), congress abstracts, official health documents, internet pages and links, slide kits, etc., The Centre collaborated with activities of the ONJ Working Group within the regional Oncology Network (Rete Oncologica) of Piemonte and Valle d'Aosta: from a register of ONJ cases seen in more than 30 hospital centres (about 600 cases observed on years 2004-2017, both in cancer and osteoporosis patients), to the development and diffusion of a data collection sheet; from meeting organization to web surveys. Furthermore, the Centre collaborated with the Italian Health Minister Commission that drafted the "Recommendations for oral health of adult cancer patients" (2014); with a regional workgroup for "Recommendations for the use of BPs in cancer patients"(2012); with the SIPMO-SICMF ONJ study group that released Italian recommendations for diagnosis and management of BP-related ONJ (2013); and with the working group for Guide Lines for treatment of metastatic cancer disease released by AIOM, Italian Medical Oncology Society (2017). The Centre also plays a role of consultancy activities (by e-mail and by phone) for physicians, dentists and patients asking for information about the ONJ issue. The Centre is continuously involved in organizing national and regional conferences since 2007, with mention to the "ONJ UPDATE. PREVENTION, DIAGNOSIS, PHARMACOVIGILANCE, TREATMENT" congress (latest edition: 5th May 2018).

**CONCLUSIONS:** The Centre is designed to be a tool for doctors, dentists, all health professionals, as well as patients and caregivers, in order to increase awareness about prevention, risk management, diagnosis, staging, treatment of ONJ.

**REFERENCES:**

1. Ministero della Salute. Raccomandazioni per la promozione della salute orale, la prevenzione delle patologie orali e la terapia odontostomatologica nei pazienti adulti con malattia neoplastica. Roma, gennaio 2014. [https://www.salute.gov.it/imgs/C\\_17\\_pubblicazioni\\_2139\\_allegato.pdf](https://www.salute.gov.it/imgs/C_17_pubblicazioni_2139_allegato.pdf)
2. LG AIOM "Trattamento delle metastasi ossee" 2017. <http://www.aiom.it/professionisti/documenti-scientifici/linee-guida/1,413,1,#TopList>
3. Fusco V *et al.* ONJ: Impact of Italian patients, and role of Italian physicians, dentists, and researchers in the growing evidence of a "new" disease. Working Paper of Public Health (12/2012)(online journal) available at [www.ospedal.al.it](http://www.ospedal.al.it)

## **F21 - Osteonecrosis of jaw (ONJ): communication issues. The project of a new national-wide newsletter**

M. Alessio\*, I. De Martino, V. Fusco, A. Baraldi, M. Rossi

*"Centro Documentazione Osteonecrosi", Oncology and Hematology Unit, Azienda Ospedaliera "SS. Antonio e Biagio e C. Arrigo", Alessandria, Italy*

**BACKGROUND:** The ONJ, or MRONJ (Medication-Related ONJ) is a complex disease. Screening, diagnosis, primary and secondary prevention (risk reduction) of ONJ are somewhat controversial and object of increasing amount of clinical experience and of scientific literature (the latter in lower measure than desirable). At the Alessandria Hospital (North-Western Italy), an ONJ Multidisciplinary Team was established on autumn 2005. This team promoted the first regional meeting about ONJ (November 2005) and the creation of an ONJ cooperative group within the regional Oncology Network (Rete Oncologica Piemonte – Valle d'Aosta). Finally on 2008 at the Alessandria Hospital the group founded a Documentation Centre about Osteonecrosis of the Jaw (Centro Documentazione Osteonecrosi) whose activity was planned to be useful to both professionals and patients. Already on September 2006, a regional newsletter was founded in order to inform all the health professionals: maxillofacial surgeons, dentists, oncologists, hematologists, nurses, radiologists, nuclear medicine and infective disease specialists, data managers. The newsletter was sent by email to a regional mailing list and published on the Oncology Network website (<http://www.reteoncologica.it/area-operatori/osteonecrosi-dei-mascellari-onj/456-documenti-e-slide/archivio>) but it arose interest in all the country and it was then sent to a national mailing list, till to 2010.

**AIM:** To renew the newsletter, enlarging the audience to a national level, adapting it to new communication media and changed needs of health professionals. To diffuse acknowledgment and awareness of ONJ epidemiology, risk factors, diagnosis tools, treatment, preventive measures.

**METHODS:** A different format was adopted and new sections were created.

**RESULTS:** A number zero issue was designed just for the national conference the "ONJ UPDATE. PREVENTION, DIAGNOSIS, PHARMACOVIGILANCE, TREATMENT" (Alessandria – Italy, 5th May 2018). Editorials with "ONJ story" in our region and in Italy have been reported. Anticipations of the 5th May themes and issues are illustrated.

Conference and congresses, in Italy and Europe, held in recent months are covered with short reports and links to abstracts and other congress acts (text, slides, etc). Future meetings, conference, society congresses are announced, with particular attention to ONJ issues. Breaking news from activities of European groups aimed to different definition and staging system will be regularly announced. One section is dedicated to the web ON-OFF platform (<http://www.sipmo.it/nuova-piattaforma-clinico-epidemiologica-per-osteonecrosi-delle-ossa-mascellari-da-farmaci/>), an useful tool planned to share ONJ clinical data among Italian specialists. Selection of published papers will be reported in the next numbers of the newsletter. Documents, news, working progress, research projects, conference coverage reports will be requested to healthcare professionals all over Italy and are already welcome.

**CONCLUSIONS:** The Newsletter is imagined as a tool for

doctors, dentists, all health professionals, in order to increase awareness about prevention, risk management, diagnosis, staging, treatment of ONJ.

**REFERENCES:**

1. Rete Oncologica website : [www.reteoncologica.it](http://www.reteoncologica.it); ONJ section : <http://www.reteoncologica.it/area-operatori/osteonecrosi-dei-mascellari-onj>
2. Fusco V *et al.* ONJ: Impact of Italian patients, and role of Italian physicians, dentists, and researchers in the growing evidence of a "new" disease. Working Paper of Public Health (12/2012)(online journal) available at [www.ospedale.al.it](http://www.ospedale.al.it)
3. M.Rapetti, I. De Martino, L. Randi, P.Pepe, V.Fusco . Osteonecrosis of Jaw (ONJ) in Italy: 2014 update of role of Italian patients, physicians, dentists, researchers. *Ann Stomatol (Roma)* 5(suppl 2) : 34, 2014 <https://www.ncbi.nlm.nih.gov/pmc/articles/PMC4377681/>

## **F22 - QEIOS — To give researchers the power to produce and share with everyone the best possible knowledge**

M. Gabriele <sup>1</sup>, A. Bedogni <sup>1</sup>, G. Bedogni <sup>2</sup>, A. Marinello <sup>3</sup>, M. Fuschi <sup>4</sup>, U. Pilla <sup>5</sup>

*<sup>1</sup>University of Padua, Padua, Italy; <sup>2</sup>University of Trieste, Trieste, Italy; <sup>3</sup>Ca' Foscari University of Venice, Venice, Italy; <sup>4</sup>University of Bologna, Bologna, Italy; <sup>5</sup>The London School of Economics and Political Science, London, UK*

**BACKGROUND:** Most of the research is inconclusive. Finding univocal answers is nearly impossible. Reasons lie both in the current systems of research production and quality check. Lack of communication among researchers at the production level brings them to the inability to select the right fundamental definitions when composing their articles. Inconsistency between definitions in related articles is the unavoidable result, leading to articles incomparability and therefore research inconclusiveness. Articles thus produced are submitted to scientific journals to be checked and published. Limited boards of reviewers select articles on their ability to foster journals' brandnames rather than on an actual quality basis. That's how this oligarchic system builds acceptance rates as low as 10%. Despite this, journal's brand-name is currently regarded as a marker of quality. What counts is where rather than what researchers publish.

**OBJECTIVES:** Qeios wants to give researchers the power to produce and share with everyone the best possible knowledge.

**METHODS:** Researchers connected on Qeios ([qeios.com](http://qeios.com)) compose their Articles along with a new object, the Definition, directly on the platform. The Definition is a new piece of knowledge which represents one of the building blocks at the base of research. Articles and Definitions are then published on the platform itself without barriers. A 100% acceptance rate for Articles and Definitions becomes essential to allow the entire researchers' community performing the most valuable quality check. Democracy is the new standard, and its power is purely exerted on what researchers publish. For the first time, a ranking of Definitions is built which determines what the best building blocks to be used in new research are. The much-sought consensus among fundamental definitions is established.

**RESULTS:** Researchers have now the power to produce and share new research of increased quality and comparability,

greatly reducing the risk of inconclusiveness and thus fuelling the entire virtuous circle.

**CONCLUSIONS:** Qeios is a totally new integrated system of research production and quality check which assists researchers in producing the best possible knowledge, while saving time, money, increasing their visibility within the scientific community, satisfying their need of democra-

cy and being economically awarded for their work. A new piece of knowledge, the Definition, and the rating system built on it allow researchers to do so. A totally new form of visibility further distinguishes Qeios — Definitions, as a whole, de facto embody a real encyclopaedia, which is expected to be the new and most reliable encyclopedic point of reference for anyone on the web.

PROOF  
MINERVA MEDICA